

Original Article

Effect Of Oestradiol On Mouse Vaginal Epithelium

Authors

Prakash Shetty, Associate Professor

Latha V Prabhu, Professor

Mangala M Pai, Assistant Professor

Department of Anatomy, Center for Basic Sciences,
Kasturba Medical College, Bejai, Mangalore- 575004, Karnataka, India.

Address For Correspondence

Dr. Prakash Shetty

Department of Anatomy, Center for Basic Sciences,
Kasturba Medical College,
Bejai, Mangalore- 575004,
Karnataka, India.

E-mail: docprakashshetty@yahoo.co.in

Citation

Shetty P, Prabhu LV, Pai MM. Effect Of Oestradiol On Mouse Vaginal Epithelium.
*Online J Health Allied Scs.*2005;4:1

URL

<http://www.ojhas.org/issue16/2005-4-1.htm>

Open Access Archives

<http://cogprints.ecs.soton.ac.uk/view/subjects/OJHAS.html>

<http://openmed.nic.in>

Submitted: Nov 09, 2005; Revised: Jan 19, 2006; Accepted: Jan 22, 2006; Published: Mar 31, 2006

Abstract:

Oestradiol which induces the proliferation of the vaginal epithelium is used in the oestrogen replacement therapy for menopausal and postmenopausal disorders. The exact onset of induced cell proliferation and recovery to the controlled level has not been reported before. Hence this study was done in ovariectomised mice and the period of cellular response to ethinyl estradiol, a semisynthetic ester (0.025mg/kg) was recorded. The vaginal epithelium was studied for histological changes and incidence of mitotic figures. The onset of proliferation started at 4h after exposure and reached its maximum at 32h and declined gradually thereafter to reach the base level at 60h.

Key Words: Oestradiol, Mitotic figures, Vaginal epithelium

Introduction

Oestradiol, a naturally occurring oestrogen or its semisynthetic esters are employed in the oestrogen replacement therapy for menopausal, postmenopausal or menstrual disorders.(1) Oestrogens impart their side effects on veterinary and human health especially on development and morphology of the reproductive system.(2) Oestrogen treatment induces 2-15 fold increase in the risk of endometrial cancer formation, with some relation to the doses and duration employed.(3) Although the role of oestrogens in the breast carcinogenesis is not clear, there seems to be some positive correlation between the use of this drug and breast cancer.(4)

Considerable number of reports is now available on the effects of oestradiol and its analogues on the vagina. Exposure of oestradiol benzoate causes anomalous vaginal development and the epithelium rapidly develops into stratified keratinized type probably due to the direct effect of steroid.(5) In ovariectomised rats, delta-tetra

hydrocannabinol induces hyperplasia of the uterus and stratification of the vaginal epithelium.(6) Oestradiol administration to the ovariectomised rats and mice results in the proliferation of the epithelium,(7, 8) even though the duration of proliferative and recovery phases was not studied. Sanyal et al (9) reported that oestradiol induces the cell proliferation in the rat vaginal epithelium. However, the onset of induced cell proliferation and its recovery to the control level in oestradiol treated vaginal epithelium is unknown and this study was planned to investigate this phenomenon in mice.

Materials And Methods

A total of 50 adult female albino swiss mice weighing 25-30g were chosen and were maintained under the standard laboratory conditions with access to food and water ad libitum. Mice were segregated into 16 groups of 3 in each except the control group, which had 9 animals. They were anaesthetized (Pentobarbitol sodium, 40 mg/kg; Sigma Chemicals), and ovariectomised as per standard procedure. (9) Two weeks after the ovariectomy, they were given a single dose of 0.025 mg of oestradiol (ethinyl oestradiol - Duoluton-L; German Remedies, Mumbai), dissolved in arachis oil. Control animals received equal quantity of oil (i.p.) only. These animals were treated with colchicines (1 mg/kg; Sigma chemicals, i.p.), dissolved in water just 2h before the sacrifice to arrest mitosis.(9) Each group of mice was sacrificed at an interval of 4h till 60h. Vagina was dissected out carefully by suprapubic incision and fixed in 10% formalin.(9) The tissue was then processed for paraffin embedding and 10 micron sections were obtained and stained with Haematoxylin and eosin. Sections from each animal were randomly selected and mitotic figures were counted in the epithelium under 40X objective of a high resolution binocular

light microscope (Olympus). The mitotic activity was estimated on the basis of area of each section and its mitotic index was expressed as the average number of mitotic figures per unit area of the epithelium (one square mm being considered as the unit area). The data were expressed as mean \pm SD and subjected to analysis by the Mann-Whitney 'U' test. $P < 0.05$ was considered as the level of significance.

Results

In ovariectomised control mice, vaginal epithelium showed decreased activity of cell division, and the mitotic figures ranged from 5-35. In ovariectomised and oestradiol treated animals, epithelial proliferation was noted after 4h following the exposure [Figure 1]

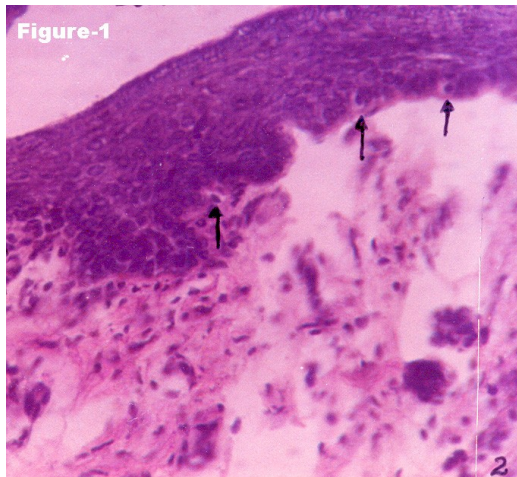


Figure 1: Microphotograph of mouse vagina (4 hr group). Slight proliferation of vaginal epithelium is seen. Arrows point the mitotic figures in the basal layer indicating an early response of vaginal epithelium to oestradiol.

This was the earliest sample time employed and following that, the incidence of mitotic figures increased as a function of time up to 32h [Figure 2]

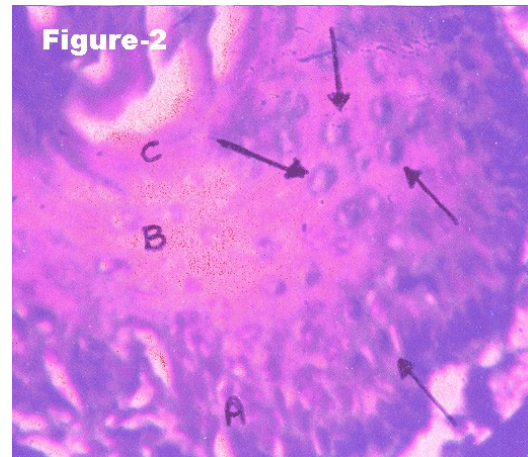


Figure 2: Microphotograph of mouse vagina (32 hr group). Maximum mitotic figures are seen in this group. Arrows indicate the mitotic figures.

At this sample time the number of cells with metaphase figures ranged from 312-476. This was the time duration required to show the maximum proliferative response of oestradiol on vaginal epithelium (Table 1).

Table 1: Effect of oestradiol on mouse vaginal epithelium (Numbers in parentheses represent the sample size. * $P < 0.001$ versus control)

Sample time	Mitotic index (Mean \pm SD)	Range
0 (9)	18.03 \pm 10.15	5-35
4 (3)	68.26 \pm 16.90*	42-113
8 (3)	107.30 \pm 19.28*	84-156
12 (3)	146.23 \pm 24.75*	102-220
16 (3)	119.43 \pm 44.15*	147-346
20 (3)	245.00 \pm 44.23*	192-388
24 (3)	287.63 \pm 43.20*	233-419
28 (3)	330.10 \pm 38.37*	280-451
32 (3)	384.76 \pm 42.82*	312-476
36 (3)	324.36 \pm 31.92*	262-422
40 (3)	211.90 \pm 26.75*	159-312
44 (3)	179.8 \pm 27.27*	145-280
48 (3)	152.43 \pm 28.11*	119-252
52 (3)	124.50 \pm 24.91*	89-204
56 (3)	78.76 \pm 18.88*	63-155
60 (3)	51.93 \pm 21.01*	33-93

From 36h onwards up to 60h, the mitotic counts decreased [Figure 3] and the minimum count at 60h was well within the control range.

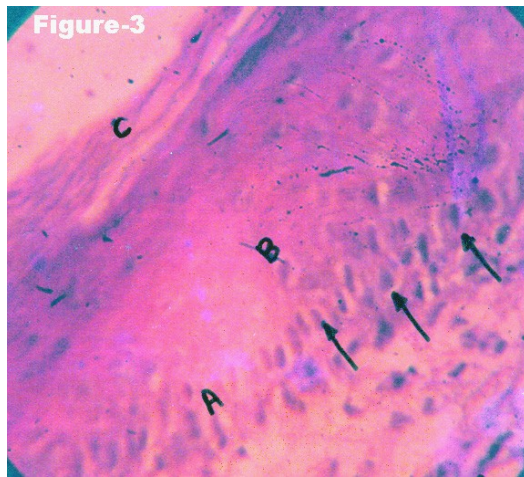


Figure 3: Microphotograph of mouse vagina (52 hr group). Mitotic figures decreased considerably and superficial cornified layer almost started desquamating into the vaginal lumen. Arrows indicate the mitotic figures. A- Basal layer, B- Intermediate layer, C- Cornified layer.

Discussion

Ovariectomy results in depletion of endogenous oestrogens, which affects the normal female sexual functions. Oestrogens, either natural or synthetic are mutagenic and carcinogenic in almost all species tested. (10) Developmental oestrogenic exposure to oestrogenic chemicals induces morphological, functional and behavioral anomalies associated with reproduction. (11) In mice, neonatal DES treatment induces persistent proliferation and keratinization of vaginal epithelium even in the absence of the ovaries resulting in cancerous lesions later in life. (12) However, the occurrence of such irreversible vaginal changes is blocked by concurrent Vit A treatment. (13) On the other hand, oestrogen exposure affects the normal embryogenesis in either sex, and

fertility parameters in experimental animals and humans.(2)

In this present study, single exposure of oestradiol enhanced the mitosis in the vaginal epithelium and this phenomenon is known to occur in the animals also. (14) However, there are no studies reporting the duration through which this mitotic activity continues following the exposure. This study has evaluated the onset of cell proliferation just at 4h following the exposure, which increased through time up to 32h. The recovery phase also takes almost same time in the mouse vaginal epithelium. This indicates that the proliferative response of mitogen oestradiol persists as a prolonged effect when given as a single treatment. In previous studies, 50 microgram of 17 beta-oestradiol on day 17 of foetal life induced ovary-independent proliferation and cornification of vaginal epithelium on postnatal day 3 in mouse.(15) Mitogenic activity of oestradiol is time dependent, and the cell division is accelerated in ovariectomised-oestradiol treated mice. This property of oestradiol is reversible by 60h after the exposure.

References

1. Parfit K. Martindale: The complete drug reference, 32nd ed. Pharmaceutical press, Massachusetts, 1999.
2. Sharpe RM, Skakkebaek NE. Are oestrogens involved in falling sperm counts and disorders of the male reproductive tract? *Lancet* 1993; 341:1392-1395.
3. Henderson BE. The cancer question: an overview of recent epidemiologic and retrospective data. *Am J Obstet Gynecol* 1989;161: 1859-1864.
4. Dupont WD, Page DL. Menopausal oestrogen replacement therapy and breast cancer. *Arch Intern Med* 1991;151: 67-72.

5. Hisano N. Effects on hamster vaginal development of single dose of testosterone on oestradiol given neonatally. *Acta Anat (Basel)* 1997;97(4): 361-370.
6. Solomon J, Cocchia MA, DiMartino R. Effect of delta-tetrahydrocannabinol on uterine and vaginal cytology of ovariectomised rats. *Science* 1977;195(5281): 875-877.
7. Ivasenko IN. Effect of simultaneous administration of oestradiol and progesterone on proliferative pool of the uterine and vaginal epithelium in castrated rats. *Arkh Anat Gistol Embriol* 1978;74(40):79-84.
8. Wong LM, Bern HA, Jones LA, Mills KT. Effect of later treatment with estrogen on reproductive tract lesions in neonatally estrogenised female mice. *Cancer Lett* 1982;17(2):115-123.
9. Sanyal AK, Singh S, Singh SP. Response of vaginal epithelium and quantitative estimation of its cellular proliferation in ovariectomised rats after a single administration of oestradiol. *Acta Anat* 1974;87:82-92.
10. Edelman DA. Diethylstilbesterol exposure and the risk of clear cell cervical and vaginal adenocarcinoma. *Int J Fertil* 1989;34(4):251-255.
11. Forsberg JG. Treatment with different antiestrogens in the neonatal period and effects in the cervicovaginal epithelium and ovaries of adult mice: a comparison to oestrogen-induced changes. *Biol Reprod* 1985;32(2):427-441.
12. Markey CM, Wadia PR, Rubin BS, Sonnenschein C, Soto AM. Long term effects of fetal exposure to low doses of the xenoestrogen bisphenol-A in the female mouse genital tract. *Biol Reprod* 2005;72(6):1344-1351.
13. Masui F, Matsuda M, Mori T. Vitamin A prevents the irreversible proliferation of vaginal epithelium induced by neonatal injection of keratinocyte growth factor in mice. *Cell Tissue Res*. 2003;311(2):251-258.
14. Tansey G, Hughs CL Jr, Cline JM, Krummer A, Walmer DK, Schmoltzer S. Effects of dietary soybean estrogens on the reproductive tract in female rats. *Proc Soc Exp Biol Med* 1998;217(3):340-344.
15. Kimura T, Kawashima S, Nishizuka Y. effects of prenatal treatment with estrogen on mitotic activity of vaginal anlage cells in mice. *Endocrinol Jpn* 1980;27(6):739-745.