Peer Reviewed, Open Access, Free
Published Quarterly
Mangalore, South India
ISSN 0972-5997
Volume 7, Issue 2; Apr-Jun 2008

Case Report

Giant intra-abdominal hydatid cysts with multivisceral locations

Authors
Sujeet Raina, Senior Resident,
Mahesh DM, PG student
Vivek Sood, PG student
Jitender K Mokta, Assistant Professor
Rajiv Raina, Associate Professor
Satinder Singh Kaushal, Professor & Head,
Department of Medicine, Indira Gandhi Medical College, Shimla - 171001 (Himachal Pradesh)

Address For Correspondence
Dr Sujeet Raina,
Fire Officers Building,
Stokes Place,,
Shimla (H.P) 171002
E-mail: sujeetrashmishera@yahoo.co.in

Citation
Raina S, Mahesh DM, Sood V, Mokta JK, Raina R, Kaushal SS. Giant intra-abdominal hydatid cysts with multivisceral locations. *Online J Health Allied Scs.* 2008;7(2):10

URL
http://www.ojhas.org/issue26/2008-2-10.htm

Submitted: April 18, 2008; Accepted: June 20, 2008; Published: July 21, 2008

Abstract:
The disseminated intra-peritoneal hydatid disease is a very rare finding. A case of disseminated intra abdominal hydatid disease is presented along with a review of literature and various therapeutic modalities.
Key Words: Hydatid cyst, peritoneal hydatosis, rectovesical hydatid cyst

Introduction:

Hydatid disease is a parasitic infection caused by the larval stage of the cestode, Echinococcus granulosus. It is endemic in many parts of the world, including India. Most frequently it affects the liver and lung. Involvement of the peritoneal cavity is uncommon, accounting for 13% of abdominal echinococcosis. Unusual locations as well as multiple primary or secondary hydatid disease pose special therapeutic challenges.(1) We report a case of disseminated abdominal hydatosis who presented with features of obstructive uropathy and investigations revealed hydatid cyst in rectovesical pouch besides liver, spleen and peritoneum.

Case Report:

A 28 year male shepherd presented with a dull aching pain and gradually increasing lump in the right hypochondrium and epigastric region over six months. There was history of acute retention of urine thrice in the past twelve days for which patient was catheterized. Anorexia and weight loss were associated complaints. History of constipation was also present. There was no history of jaundice. He was operated upon for hepatic hydatic disease seven years back. Examination revealed multiple cystic swellings in abdomen. Hepatospleenomegally was present. Both liver and spleen were having irregular surface with multiple, nontender cystic masses palpable over the surface. Soft irregular masses were also felt in the umbilical and hypogastric regions. On per rectal examination, a mass was felt from anterior rectal wall but rectal mucosa was free. Review of other systems was normal. On laboratory investigations hemogram revealed mild increase in the eosinophil count (3%) and raised ESR (55mm at the end of 1 hour) , Biochemistry screen revealed normal investigations including a normal liver function profile. Test for antibodies against *Echinococcus granulosus* was 15.99 U/ml and was positive. Ultrasound examination of the abdomen and pelvis revealed multiple, thin walled cystic lesions of variable size in the liver and spleen with cartwheel appearance. The peritoneum and the pelvis were studded with similar cystic lesions. Plain CT scan of the abdomen revealed multiple, well defined cystic lesions throughout the abdomen.(Fig-1) The cysts were multi loculated with multiple internal septations suggestive of hydatid disease. Liver and spleen appear to be replaced by the multiseptated cysts.(Fig-2) A large cyst is seen in the pelvic cavity producing a pressure affect on surrounding structures but not invading them.(Fig-3) A diagnosis of secondary echinococcosis was made on clinical features and investigations. Patient was started on albendazole (15mg/kg/day) and follow up was advised. Patient has been lost in the follow up.

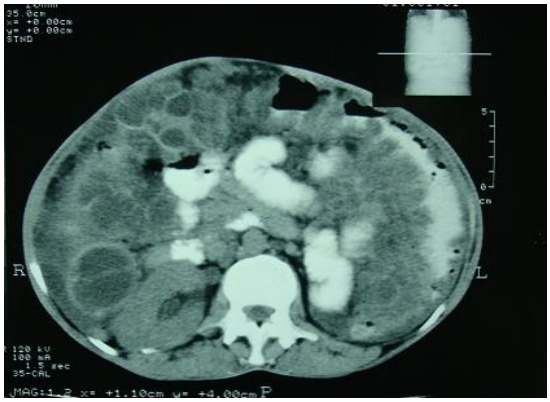

Figure-1 CT abdomen showing peritoneal hydatid cyst

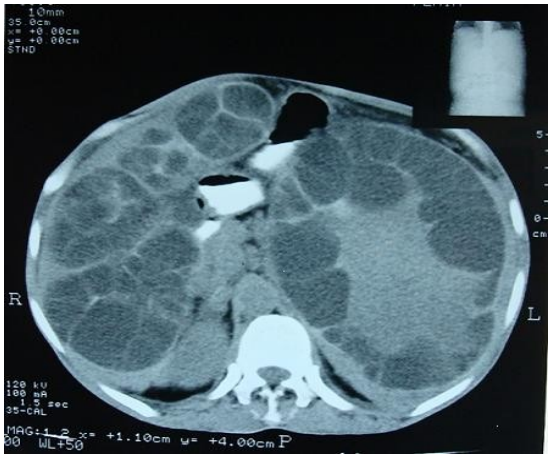

Figure-2 CT abdomen showing hydatid cyst in liver and spleen

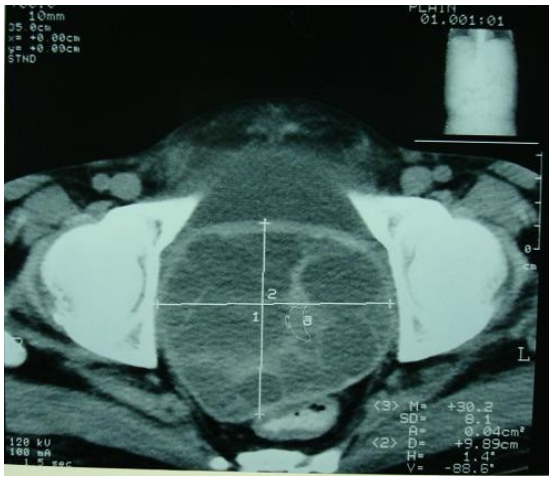

Figure-3 CT abdomen showing hydatid cyst in rectovesical pouch

ojhas Online Journal of Health and Allied Sciences

Discussion:

Hydatid disease is a parasitic disease caused by the larval stage of *Echinococcus granulosus*. Hydatid disease remains a continuous public health problem in endemic countries including India. The most frequently involved organs are the liver (55-70%) followed by the lung (18-35%); these two organs affected simultaneously in about 5-13% of cases, the spleen (5%) and other organs (5%).(1-2) Apart from common sites such as liver and lungs in humans, hydatid cysts can present in unusual sites which include peritoneum, kidney, muscle, adrenal gland, ovary, pancreas, thyroid gland, pleura, diaphragm, uterus and brain.(1) The peritoneal hydatid disease represents an uncommon occurrence with an overall frequency of peritoneal disease in cases of abdominal echinococcus at approximately 13%. Peritoneal hydatidosis is almost always secondary to hepatic disease, although some unusual cases of primary peritoneal hydatidosis have been described. Peritoneal involvement is usually undetected unless cysts are large enough to cause symptoms. Most of the cases of peritoneal hydatid disease are secondary to previous surgery for liver hydatidosis; however, spontaneous microrupture of a hepatic cyst into peritoneum has also been reported. Intraperitoneal rupture of hepatic or splenic cysts results in release of brood's capsule, scolices and daughter cysts which implant and develop independently leading to multiple disseminated intraperitoneal hydatid disease. This phenomenon is called secondary echinococcosis.(3)

Peritoneal hydatid disease may grow and occupy the entire peritoneal cavity, simulating a multilobulated mass. This pathological condition is known as encysted peritoneal hydatidosis. Peritoneal hydatid disease represents an uncommon occurrence and its diagnosis is more accurate today due to the new imaging techniques.(4) A double contrast CT scan is 90-100% accurate for diagnosing secondary echinococcosis and is superior to USG in identifying additional extrahepatic intra abdominal cysts.(3) CT is the modality of choice for these patients because it permits imaging of the entire abdomen and pelvis.(5)

The goal of treatment is to prevent secondary complications of the disease. In cases of disseminated systemic disease, inoperable cases, cyclic therapy with a benzimidazole compound is preferred and has been found to cure disease in 10-30% of cases, to slow progression in 50%-70% and to yield no change in 20%- 30%.(6) Albendazole seems to be more effective owing to better penetration and absorption. These agents have actually been used in several studies as a conservative treatment, leading to some decrease or stabilization of the cyst size, especially in cases with small cysts. Albendazole is combined with surgery to prevent postoperative recurrence.(2) After medical therapy, follow up is advisable with USG or CT scan. After medical treatment, hydatid cysts shows gradual reduction in cyst size and number. The cyst becomes poorly defined and denser. Daughter cysts may disappear or may rupture and the laminated membrane may separate from the pericyst and collapse. Thickening and calcification of the cyst wall can be taken as therapeutic response if it was absent before treatment. Cyst disappearance should be regarded as the criteria with most promising prognostic value.

Surgical removal of the cyst is customized to each patient depending on the patient's general condition, the number and localization of cysts, and the surgeon's expertise.(1-2) Recurrence of hydatid disease after after radical procedures is very low, but not zero and the possibility of recurrence always remains.(2) PAIR(puncture, aspiration, instillation of scolicidal agents and reaspiration) technique is also possible in cysts relapsing after surgery or failed chemotherapy. However PAIR is contraindicated in cysts that communicate with biliary tree, superficial cysts and cysts with thick internal septal divisions.(7)

The purpose of reporting this case is to highlight the uncommon presentation of hydatid disease due to multivisceral and peritoneal locations.

References:

1. Syed Abdullah Iqbal, Masood Jawaid, Fareya Usmani: Disseminated Intra-Abdominal Hydatidosis: A Very Rare Presentation. *The Internet Journal of Surgery*. 2007;11:1.
2. Safioleas MC, Misiakos EP, Kouvaraki M, et al. Hydatid Disease of the Liver. *Arch Surg*. 2006;141:1101-8
3. Sahu SK, Singh P, Sachan PK,et al. Secondary echinococcosis. *Indian J Surg* 2006;68:334-5.
4. Tarcoveanu E, Dimofte G, Bradea C,et al. Multiple Peritoneal Hydatid Disease after Rupture of a Multivesicular Hepatic Hydatid Cyst. Case report. *J Gastrointestin Liver Dis* 2006;15:301-5
5. Yuksel M, Demirpolat G, Sever A, et al. Hydatid disease involving some rarelocations in the body: a pictorial essay. *Korean J Radiol* 2007;8:531-40
6. Karmali S, Thompson SK, McKinnon G, et al. A 37-year-old woman with fever and abdominal-pain. *CMAJ* 2005;172:1683.
7. White CA, Weller PF. Cestodes. In: Kasper DL, Braunwald E, Fauci SA, Hauser SL, Longo DL, Jameson JL, eds. Harrison's Principles of Internal Medicine. 16th ed. New York. McGraw-Hill.2005. pp 1275-76