Online Journal of Health and Allied Sciences
Peer Reviewed, Open Access, Free Online Journal
Published Quarterly : Mangalore, South India : ISSN 0972-5997
Volume 9, Issue 3; Jul-Sep 2010

Case Report:

Primary Cutaneous Low Grade Mucinous Adenocarcinoma of Eyelid

Geethalakshmi U, Assistant Professor Department of Pathology,
Vijayshankar S Assistant Professor, Department of Pathology,
Abhishek MG, Assistant Professor, Department of Pathology,
Indira CS, Tutor, Department of Pathology,
Adichunchanagiri Institute of Medical Sciences, BG Nagara, Bellur cross, Mandya district, Karnataka, India.

Address For Correspondence:
Dr U Geethalakshmi,
Assistant Professor,
Department of Pathology,
Adichunchanagiri Institute of Medical Sciences,
B.G.Nagara, Bellur cross,
Mandya district, Karnataka, India.
E-mail: ugeeths_ganesh@yahoo.co.in

Citation: Geethalakshmi U, Vijayshankar S, Abhishek MG, Indira CS. Primary Cutaneous Low Grade Mucinous Adenocarcinoma of Eyelid. *Online J Health Allied Scs.* 2010;9(3):18
URL: http://www.ojhas.org/issue35/2010-3-18.htm
Open Access Archives: http://cogprints.org/view/subjects/OJHAS.html and http://openmed.nic.in/view/subjects/ojhas.html

Submitted: Jul 30 2010; Accepted: Sep 25, 2010; Published: Oct 15, 2010

Abstract:
Primary cutaneous mucinous adenocarcinoma is a rare adnexal neoplasm, eyelid being the most common site of presentation. Clinically it is mistaken for a benign / cystic lesion. Its morphologic similarity to metastatic deposits from breast, gastrointestinal tract (GIT) or any visceral sites adds to the diagnostic difficulty mandating the role of ancillary techniques in precise diagnosis and hence planning the management. We report a case of primary cutaneous mucinous adenocarcinoma of eyelid with emphasis on pathology along with a brief review of literature.
Key Words: Mucinous adenocarcinoma; Eyelid; Immunohistochemistry

Case Report:
A 45 year old male presented for evaluation of a painless nodular lesion over lateral aspect of right upper eyelid, slowly growing in size over duration of five years. There was no lymphadenopathy. On examination it was a skin colored nodule measuring 1x 0.5 x 0.5cm. The swelling was fluctuant with positive transillumination test. Clinical diagnosis of benign cystic lesion with a possibility of hydrocystoma was considered. The mass was excised under local anaesthesia and sent for histopathological examination.

Gross examination revealed a grey tan subcutaneous nodule measuring 1x 0.5 x 0.5cms. Cut section was solid and gelatinous with areas of haemorrhage (Figure 1). Microscopy showed a dermal tumour composed of epithelial cells in nests (Figure 2), glandular, cribriform and micropapillary pattern surrounded by lakes of mucin, divided into lobules by fibrovascular septa along with foci of haemorrhage. Lateral margins were free from tumour while deep resected margin was involved.

On histochemistry the mucin was PAS positive, diastase resistant, alcian blue positive and hyaluronidase resistant at pH 2.5. Tumor cells immunohistochemically expressed EMA and CK 7. Tumor was negative for CK20, CD10, p63 and TTFI. Extensive search for primary mucinous carcinoma elsewhere was negative. Thus a final diagnosis of primary cutaneous mucinous adenocarcinoma was made.

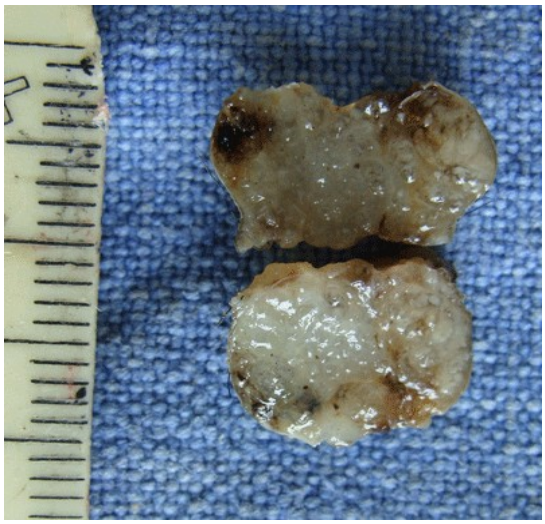

Figure 1: Gross appearance of the specimen

Discussion:
Primary cutaneous mucinous adenocarcinoma of eyelid is a rare neoplasm believed to arise from eccrine type of sweat glands. It occurs commonly in males in sixth decade of life. Head and neck are the most common sites affected especially the eyelid.[1] The other common sites are scalp, face, axilla, rarely abdomen, groin, foot and vulva. Clinically it appears as a solitary painless, slow growing nodule. As a result malignancy is never considered as a possibility by the ophthalmologist, when clinical appearance is considered.

Histopathologically tumour is subepithelial comprising of tumour cells arranged in cohesive nests, glandular, cribriform and micropapillary pattern surrounded by pools of mucin separated by thin fibrous septa. Individual cells are cuboidal with moderate amount of eosinophilic cytoplasm.[2] Microscopy closely mimics colloid carcinoma breast. The differential diagnosis of primary mucinous adenocarcinoma includes meta-

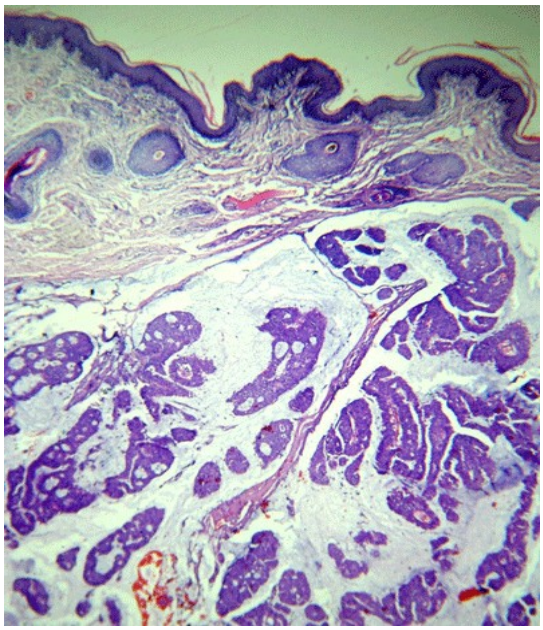

Figure 2: Photomicrograph shows dermal tumour composed of epithelial cells in nests (Haematoxylin and Eosin, X 450).

static mucinous adenocarcinomas from breast, GIT (mainly stomach, colon, pancreas and rectum), ovary, prostate, bronchus and salivary glands.[3]

The distinction between primary and secondary mucinous carcinomas cannot be done on histologic grounds alone. Mucin histochemistry is distinctive and would allow a correct diagnosis.[4,5] Mucin produced in primary mucinous carcinoma is PAS positive, diastase resistant and alcianblue positive, hyaluronidase resistant at pH 2.5. It also stains positive for mucicarmine and colloidal iron. Mucin belongs to nonsulphated sialomucin.

At immunohistochemistry EMA and CK 7 positivity confirms the primary carcinoma.[3,5,6] Additional studies like enzyme histochemistry and electron microscopy help in confirming the sweat gland origin. Enzyme histochemistry reveals eccrine enzymes commonly. Electron microscopy shows two types of cells-dark cells and light cells. Dark cells are responsible for secretion of sialomucin.

Primary mucinous carcinoma is a slow growing neoplasm with high recurrence rate.[7] Tumor is locally aggressive but metastasizes rarely. Treatment is mainly surgical in the form of wide local excision. Chemotherapy and radiotherapy have a limited role.

Conclusion:

Primary cutaneous mucinous adenocarcinoma mimics a benign non neoplastic lesion of the eyelid clinically and metastatic mucinous carcinoma histologically. The present case underscores the importance of considering this in differential diagnosis of any solid/cystic eyelid lesion. A close coordination between a surgical pathologist and ophthalmologist is must for precise diagnosis and appropriate management.

References:

1. Snow SN, Reizner GT. Mucinous eccrine carcinoma of the eyelid. *Cancer.* 1992;70:2099-2104
2. Mckee PH, Colonje E, Granter SR. Primary mucinous carcinoma. Pathology of skin with clinical correlation. 3rd Edition Elsevier, Mosby. 2005. pp1656-1659
3. Randhwa NK, Wong MTC. Primary mucinous carcinoma of the skin-a case report. *Eur J Plast Surg.* 2009;32:315-317
4. Schwartz RA, Weiderkehr M, Lamber WC. Secondary mucinous carcinoma of skin – metastatic breast carcinoma. *Dermatol Surg.* 2004;30:234-235
5. Bellezza G, Sidoni A, Bucciarelli E. Primary mucinous carcinoma of skin. *Am J Dermatopathol.* 2000;22:166-170
6. Levy G, Finkelstein A, McNiff JM. Immunohistochemical techniques to compare primary vs. metastatic mucinous carcinoma of the skin. *J Cutan Pathol.* 2009;9:24
7. Chauhan A, Ganguly M, Takkar P, Dutta V. Primary mucimous carcinoma of eyelid: A rare clinical entity. *Indian J Ophthalmol.* 2009;57:150-152