



Short Review:

Complications of Dermal Filling

Sajad Ahmad Salati,

Assistant Professor of Surgery, College of Medicine, Qassim University, Saudi Arabia.

Address for Correspondence:

Dr. Sajad Ahmad Salati,

Assistant Professor of Surgery,

College of Medicine,

Qassim University,

Saudi Arabia.

E-mail: docsajad@yahoo.co.in

Citation: Salati SA. Complications of Dermal Filling. *Online J Health Allied Scs.* 2011;10(3):9

URL: <http://www.ojhas.org/issue39/2011-3-9.htm>

Open Access Archives: <http://cogprints.org/view/subjects/OJHAS.html> and <http://openmed.nic.in/view/subjects/ojhas.html>

Submitted: Jul 28, 2011; Accepted: Oct 22, 2011; Published: Nov 15, 2011

Abstract: Dermal fillers have globally become sought after drugs due to the desire of aging population to regain the youthful looks without any surgical operations. But like other procedures, dermal filling can become complicated. Besides the profitability have introduced the factor of malpractice which can bring in misery rather than beauty and youthful body contours. This article briefly reviews the common adverse effects of dermal fillers.

Key Words: Dermal fillers; Complications; Consent; Malpractice

Introduction:

Dermal fillers have brought in a virtual revolution in the field of cosmetic surgery in recent years¹⁻². These fillers have provided a safe and effective method for neutralizing the effects of aging and stress and regain a youthful and healthy appearance without coming under the sharp knives of surgeons and with minimal down time. These drugs have been widely advertised and marketed by pharmaceutical companies and the concept of soft tissue augmentation is continuously attracting aging people who are eager to look better.

However with the widespread surge on the use of dermal fillers for body rejuvenation, a new disease entity in the form of adverse outcomes and complications of these cosmetic procedures are being reported in the literature³⁻⁷. The adverse effects to dermal fillers can be attributed to the procedure itself, the procedural technique, and the agent injected⁵. Among these factors, the injection techniques have been reported to be most significant in present era of temporary fillers⁶. The faulty techniques by novice or unqualified or greedy practitioners have been the cause for most of the miserable outcomes after these cosmetic procedures.

Complications of Dermal Fillers

The complications of dermal fillers are varied and include:

Transient /predictable complications

There are certain transient and predictable complications which include erythema, edema and ecchymoses. They may occur immediately after the procedure or present hours after the injections are completed. In some studies, such transient adverse events related to dermal filling have been reported in as high as 21.5%⁶ of the injections. Ecchymoses is usually minor and resolves without intervention after 2 to 3 days. Although ice packs and cooling after injections can increase patient comfort, they have not been found to be efficacious in reducing post-operative edema.

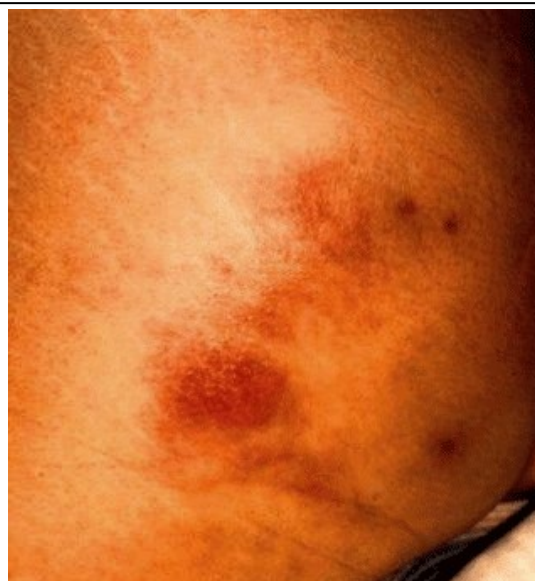

Fig 1: Edema and ecchymosis after gluteal dermal filling

More significant ecchymoses may develop in patients who consume alcohol, anticoagulants or nonsteroidal anti-inflammatory drugs, or certain herbal medications associated with prolonged bleeding; examples include vitamin E, ginger, garlic, ginseng, and ginkgo biloba. The herbal medications are often underreported by patients in the screening process. Ciocon et al recommend discontinuing these agents at least 1 week prior to major procedures although bleeding time may take 2 to 3 weeks to fully correct.⁸

Besides the technique and expertise of the injector are also important determinants of immediate complications. In this regard, Gladstone et al has reported that the fanning injection technique for dermal fillers can also increase the likelihood of bleeding.⁹

Infection

Infections associated with dermal filling can appear early as acute infection or late as chronic infection. Acute infections generally occur due to breach of aseptic techniques should be rare in expert hands. These early infective lesions in form of in-

flammation or even abscesses may be due to common skin and soft tissue pathogens, including *Staphylococcus aureus*.³

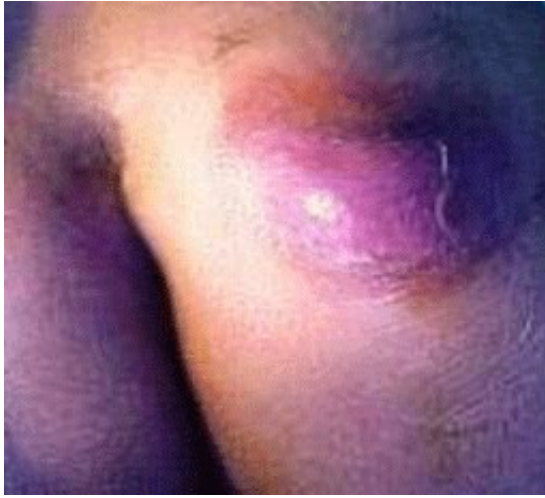

Fig 2: Multiple gluteal abscesses after dermal filling

Lesions that develop more than 2 weeks post dermal filling might even suggest the presence of an atypical infection, and mycobacteria also need to be considered as causative organism. Besides, dermal filling can lead to reactivation of herpes infections. Infection may also be due to faulty products and outbreaks of mycobacterial infections have been reported to use of tainted dermal fillers by nonphysicians.¹⁰ Similarly there are reports of chronic abscess formation due to organisms like *E. coli* even as late as seven years after dermal filling with Bio-Alcamid.¹¹

Skin Discoloration

Significant skin discoloration can occur at the site of treatment; this typically occurs immediately after injection and generally resolves within a few weeks as mentioned before.³ Reddish discoloration signifies an inflammatory response, whereas pallor at the injection site can be attributed to overcorrection or the color of the injected substance. Hyperpigmentation (which can be treated with depigmentary cream) and bluish discoloration have also been reported, particularly in cases of products containing hyaluronic acid. The bluish hue may represent both traces of hemosiderin associated with vascular injury and visual distortion from light refraction to the filler through the skin (Tyndall effect) due to superficial deposition.

Hypersensitivity reactions

Dermal fillers are essentially foreign bodies and some patients may develop hypersensitivity to injected products due to an exaggerated immune response. Such reactions generally occur within minutes of exposure to a challenging antigen owing to the release of histamine, and manifest as edema, erythema, pain, and itching. These allergic reactions can be severe¹⁵, and cases of severe angio-edema and anaphylactic shock have been reported in literature.¹⁶

Nodule/ granuloma formation

Nodules may be inflammatory or noninflammatory and infection-or noninfection-related and may present subcutaneously or in the dermis¹⁴⁻¹⁵. Non-erythematous, painless nodules occurring earlier than 2 weeks are likely related to uneven filler placement¹⁶, but pain, erythema and fluctuation may indicate infection. Intermediate to late nodule complications, arising 2 weeks to 1 year post injection, and delayed nodules noted beyond 1 year, may be immune responses to the filler or infectious granulomas. Delayed onset fibrotic nodules may be seen with poorly placed particulate stimulatory filler, such as poly-L-lactic acid and calcium hydroxyl apatite, especially in mobile areas,

such as the lip, or with the use of poly-L-lactic acid, particularly because of the inadequate dilution of filler.

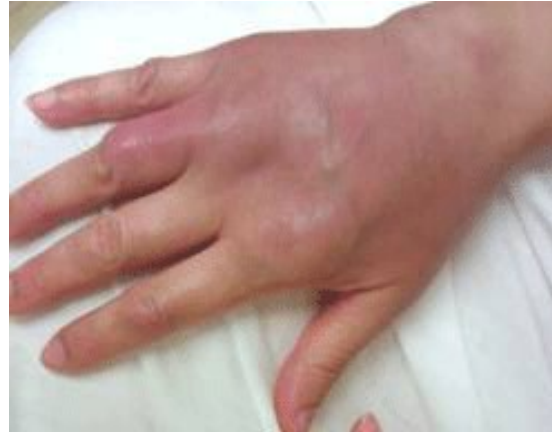

Fig 3: Multiple nodules over dorsum of hand one year after dermal filling with silicone.

Asymmetry

Dermal fillers may temporarily produce a bloated appearance but a major complication which occurs as a result of poor filling technique is under/over correction leading to asymmetry and ugly outcomes. Overcorrection of the upper lip can lead to a “duck bill” appearance. Asymmetry due to temporary fillers resolves with time but if permanent fillers are injected, the asymmetry will be a cosmetic and mental disaster.

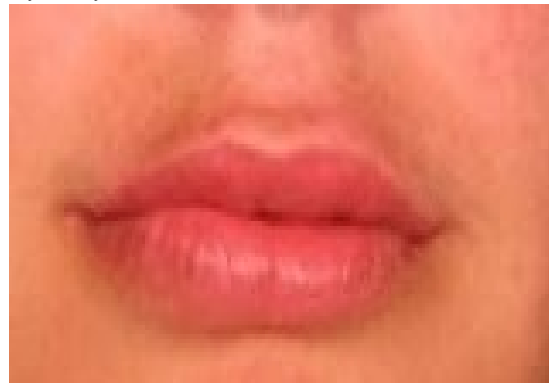


Fig 4 : Asymmetrical lips after dermal filling

Skin necrosis

Injection necrosis is a rare but clinically important and serious potential complication of dermal filling. This results from interruption of the vascular supply to the area by compression, injury, and/or obstruction of the vessel(s).¹⁷⁻¹⁸ It may occur when the material is injected into the angular artery of the nasolabial fold or the supratrochlear artery in the glabellar region. Compression of the supratrochlear vessels during injection of the filler has been proposed as a technique to minimize this complication.

Miscellaneous complications

In the literature, there are many other complications reported with use of dermal fillers which are uncommon but are potentially serious. These include:

Embolism

Filler injections in the gluteal area have been reported by Coronado-Malagón M et al¹⁹ to result in fat embolism. Pulmonary embolism has been reported by Hyung Joo Park et al²⁰ as a serious consequence of vaginal filling with hyaluronic acid based filler. Even cerebral artery embolism with resultant neuro-deficit have been reported.²¹

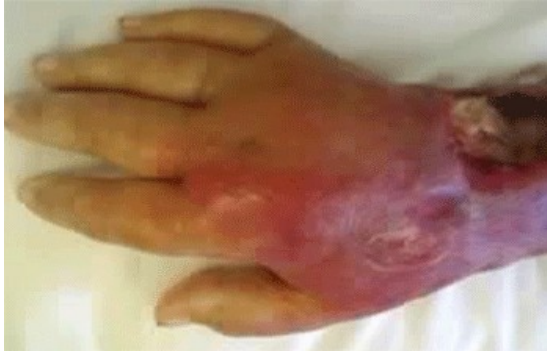

Fig 5: Skin necrosis over dorsum of hand after dermal filling

Ocular complications

The retinal artery and posterior ciliary arteries are proximal branches of the ophthalmic artery. Multiple superficial arteries of the face are distal branches of the ophthalmic artery (supra-orbital, supratrochlear, dorsal nasal, angular artery of the nose). A cannula or needle used to inject a soft tissue filler can accidentally perforate the wall of one of the distal branches and enter the artery's lumen and when the plunger of the syringe is pressed to propel the injectable filler out of the syringe, the filler gets injected into the lumen of the cannulated artery. The filler displaces the arterial blood and travels as a column proximally past the origin of the retinal artery. As the forced injection ceases at the end of procedure, the arterial systolic pressure propels the filler anterograde flow into retinal central artery and anterior and long posterior ciliary arteries leading to blindness, corneal and iris ischaemia, and total ophthalmoplegia. There are many such reports published in literature.²²⁻²⁵

Diagnostic difficulties

The patients can presents as lumps and bumps simulating malignant lesions. The diagnostic difficulties are more in cases that conceal the history of dermal filling and result in battery of investigations. Many times the issues are settled only after histopathological analysis of the lesions.²⁶

Management of Complications

Management of the complications of dermal fillers depends on the nature of the adverse effect and the nature of the filler. But due to profitability of this cosmetic procedure, unscrupulous practitioners are being reported globally to inject substandard and unauthorized products without detailing the patients about the nature of products. Or else, the patients might be reluctant to volunteer the history of dermal filling due to social inhibitions and may create a challenging situation in diagnosis and management. In our series, majority (51%) of the cases was unaware of the nature of the injected filler. If however the nature of filler is known, multiple medical means to reverse the adverse effects can be tried. These include the use of local/ systemic steroids, hyaluronidase, antibiotics, analgesia and anti-inflammatory drugs besides counseling and physical methods like cold sponging. Wiest LG et al have successfully treated granulomas arising from permanent fillers containing microparticles with a hydrophobic surface like hydroxymethylmethacrylate and ethylmethacrylate were treated with good results with a regimen of allopurinol and intralesional injections with a mixture of fluorouracil and low-dose triamcinolone.²⁷ Surgical intervention has a role in management complications²⁸ and may include drainage of abscesses, revision of scars, and excision of granulomas and nodules.

To avoid such ocular complications, Coleman R S recommends using larger, blunt cannulas and epinephrine at the injection site, while avoiding the injection of large boluses of soft tissue filler in the face.²⁹

Administration of dermal fillers without proper informed consent widely mentioned in literature.³⁰ It is must that the people are informed about all the aspects of dermal filling with particular emphasis on complications before embarking on these procedures.

Conclusion

Dermal fillers are an important recent advance in cosmetic dermatology but it has the potential to produce complications particularly in hands of untrained or uncertified hands. There is need to improve the level of knowledge among the general population regarding positive and negative effects of dermal fillers.

References:

1. Klein AW. Soft tissue augmentation 2006: filler fantasy. *Dermatol Ther.* 2006;19(3):129-133.
2. Carruthers J, Cohen SR, Joseph JH, Narins RS, Rubin M. The science and art of dermal fillers for soft-tissue augmentation. *J Drugs Dermatol.* 2009;8(4):335-350.
3. Christensen L, Breiting V, Janssen M, Vuust J, Hogdall E. Adverse reactions to injectable soft tissue permanent fillers. *Aesthetic Plast Surg.* 2005;29(1):34-48.
4. Hirsch RJ, Stier M. Complications of soft tissue augmentation. *J Drugs Dermatol.* 2008;7(9):841-845.
5. Nicholas J, Lowe C, Maxwell A, Patnaik R. Adverse Reactions to Dermal Fillers: Review *Dermatol Surg* 2005;31:1616-1625
6. Xiao-qing Y, Li-yang C, Lu-ping H, Lei Y et al. A multicenter study of Restylane for treatment of nasolabial folds in China. *Chin Med J (Engl).* 2010;123(2):173-177
7. Glogau RG, Kane MA. Effect of injection techniques on the rate of local adverse events in patients implanted with nonanimal hyaluronic acid gel dermal filler. *Dermatol Surg* 2008;34(1):S105-109.
8. Ciocon JO, Ciocon DG, Galindo DJ. Dietary supplements in primary care: Botanicals can affect surgical outcomes and follow-up. *Geriatrics* 2008;59:20-24.
9. Gladstone HB, Cohen JL. Adverse effects when injecting facial fillers. *Semin Cutan Med Surg.* 2007;26:34-39.
10. Newman MI, Camberos AE, Ascherman J. Mycobacteria abscesses outbreak in US patients linked to offshore surgicenter. *Ann Plast Surg.* 2005;55:107-110
11. Campana M, Lazzeri D, Rosato L, Perello R et al. Late-onset gluteal escherichia coli abscess formation 7 years after soft tissue augmentation with bio-Alcamid in a HIV-positive patient. *J Plast Reconstr Aesthet Surg.* 2010;63(9):e709-710.
12. Van Dyke S, Hays GP, Caglia AE, Caglia M. Severe acute local reactions to a hyaluronic acid-derived dermal filler. *J Clin Aesthetic Dermatol.* 2010;3(5):32-35.
13. Mullins RJ, Richards C, Walker T. Allergic reactions to oral, surgical and topical bovine collagen. Anaphylactic risk for surgeons. *Aust NZ J Ophthalmol* 1996;24:257-260.
14. Narins RS, Coleman WP, Glogau RG. Recommendations and treatment options for nodules and other filler complications. *Dermatol Surg* 2009;35(suppl 2):1667-1671.
15. Friedman PM, Mafong EA, Kauvar ARM et al. Safety data of injectable nonanimal stabilized hyaluronic acid gel for soft tissue augmentation. *Dermatol Surg* 2002;28:491-94.
16. Lowe NJ, Maxwell CA, Lowe P et al. Hylaronic acid skin fillers: adverse reactions and skin testing. *J Am Acad Dermatol* 2001;45:930-933.
17. Hirsch RJ, Cohen JL, Carruthers JD. Successful management of an unusual presentation of impending necrosis following a hyaluronic acid injection embolus and a proposed algorithm for management with hyaluronidase. *Dermatol Surg.* 2007;33:357-360.

18. Glaich AS, Cohen JL, Goldberg LH. Injection necrosis of the glabella: protocol for prevention and treatment after use of dermal fillers. *Dermatol Surg.* 2006;32:276-281.
19. Coronado-Malagón M, Visoso-Palacios P, Arce-Salinas CA. Fat embolism syndrome secondary to injection of large amounts of soft tissue filler in the gluteal area. *Aesthet Surg J.* 2010;30(3):448-450.
20. Park HJ, Jung KH, Kim SY, Lee JH et al. Hyaluronic acid pulmonary embolism: a critical consequence of an illegal cosmetic vaginal procedure. *Thorax* 2010;65:360-361
21. Egido J, Arroyo R, Marcos A, Jiménez-Alfaro I. Middle cerebral artery embolism and unilateral visual loss after autologous fat injection into the glabellar area. *Stroke* 1993;24:615-616.
22. Tangsirichaipong A. Blindness after Facial Contour Augmentation with Injectable Silicone. *J Med Assoc Thai* 2009;92 (Suppl 3):S85-87
23. Shin H, Lemke BN, Stevens TS, Lim MJ. Posterior ciliary-artery occlusion after subcutaneous silicone oil injection. *Ann Ophthalmol* 1988;20:342-344.
24. McCleve D, Goldstein JC. Blindness secondary to injections in the nose, mouth, and face: cause and prevention. *ENT Journal* 1995;74:182-188.
25. Silva MTT, Curi AL. Blindness and total ophthalmoplegia after polymethylmethacrylate injection. *Arq Neuropsiquiatr* 2004;62(3-B):873-874
26. Karagozoglu KH, van der Waal I. Polyacrylamide soft tissue filler nodule mimicking a mucoepidermoid carcinoma. *Int J Oral Maxillofac Surg.* 2008;37(6):578-580.
27. Wiest LG, Stolz W, Schroeder JA. Electron microscopic documentation of late changes in permanent fillers and clinical management of granulomas in affected patients. *Dermatol Surg.* 2009;35 Suppl 2:1681-1688.
28. Wolfram D, Tzankov A, Piza-Katzer H. Surgery for foreign body reactions due to injectable fillers. *Dermatology.* 2006;213(4):300-304.
29. Coleman SR. Avoidance of arterial occlusion from injection of soft tissue fillers. *Aesthet Surg J.* 2002;22(6):448-450.
30. Lombardi T, Samson J, Plantier F, Husson C, Küffer R. Orofacial granulomas after injection of cosmetic fillers. Histopathologic and clinical study of 11 cases. *J Oral Pathol Med.* 2004;33(2):115-120.