



Case Report:

Primary Transitional Cell Carcinoma of the Fallopian Tube

Kavita Mardi, Associate Professor,
Vijay Kaushal, Professor & Head,
Dept. of Pathology, Indira Gandhi Medical College, Shimla.

Address for Correspondence:

Dr. Kavita Mardi,
12-A, Type V Quarters,
GAD Colony, Kasumpti,
Shimla, Himachal Pradesh, India.
E-mail: kavitamardi@yahoo.co.in

Citation: Mardi K, Kaushal V. Primary Transitional Cell Carcinoma of the Fallopian Tube. *Online J Health Allied Scs.* 2011;10(4):8

URL: <http://www.ojhas.org/issue40/2011-4-8.htm>

Open Access Archives: <http://cogprints.org/view/subjects/OJHAS.html> and <http://openmed.nic.in/view/subjects/ojhas.html>

Submitted: Dec 5, 2011; Accepted: Jan 5, 2012; Published: Jan 15, 2012

Abstract: Primary carcinoma of the fallopian tube is a rare entity that accounts for 0.2-0.5% of all gynecologic malignancies, and most are discovered during or after surgery. Primary transitional cell carcinoma of the fallopian tube is an extremely rare tumor that is reported only occasionally in the worldwide literature. As primary transitional cell carcinoma (TCC) of the fallopian tube is so rare, the clinicopathologic characteristics are as yet unknown. The authors recently experienced a case of primary transitional cell carcinoma arising in the left fallopian tube and thus report the clinical features, management, and also a review of the past pertinent literature. A 52 years old woman presenting with lower abdominal pain was found to have a left adnexal mass. Exploratory laparotomy revealed a mass arising from the left fallopian tube with the histologic features of transitional cell carcinoma.

Key Words: Transitional cell carcinoma; Fallopian tube.

Introduction:

Transitional cell carcinoma arising from the fallopian tube is an exceedingly rare entity that accounts for 0.2-0.5% of all gynecologic malignancies.¹⁻³ We herein report one such rare occurrence in a 52 years old female.

Case Report:

A 52 years old lady presented with intermittent colicky lower abdominal pain of 1-month duration. She had Attained menopause 5 years back. Her bladder and bowel habits were normal. On examination, she was of average build with good performance status. Her vitals were stable, with no pallor, edema or lymphadenopathy. On vaginal examination, a left adnexal mass of about 3cm diameter was felt. However, per rectal examination did not reveal any mass in the pouch of Douglas (POD).

Patient was evaluated with routine blood investigations, tumor markers and imaging, including ultrasound and a CT scan of the abdomen and pelvis. Thus, with a provisional diagnosis of ovarian malignancy, the patient underwent a staging laparotomy. Per-operatively, there was 3x3cm sized, well circumscribed mass arising from the left fallopian tube. Cut section of the mass was soiled, grey white with necrotic and hemorrhagic areas. Both the ovaries, on gross examination, appeared apparently normal (Figure1). No obvious deposits were found on the POD, abdominal or diaphragmatic peritoneal surfaces. Liver and omentum appeared free of disease. No significantly enlarged pelvic or para-aortic nodes were present. Histologically, the tumor

surrounded the lumen of the left fallopian tube and was composed of cells with "coffee-bean"-like nuclei arranged in solid nests without keratinization. Focally the tumor cells are arranged around papillae with fine fibrovascular cores (Figure2). In addition, there were areas of necrosis in the center of sheets of tumor cells. PAS and Mucicarmine stains were negative. No abnormalities were found in the right tube, ovaries, or uterus. The diagnosis of primary transitional cell carcinoma of the fallopian tube was rendered.



Figure 1: Gross photograph revealing cut section of the growth arising from the left fallopian tube

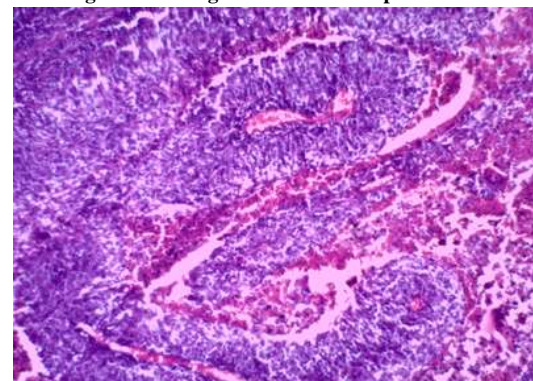


Figure 2: Photomicrograph revealing papillae with fibrovascular cores lined by malignant transitional epithelium.(H&E,20x)

Discussion:

Primary Fallopian tube carcinoma (PFTC), first described by Renaud in 1847, is the least common gynecological malignancy encountered in practice. These tumors constitute 0.2 – 0.5% of primary female genital malignancies.¹⁻³ In primary tubal malignancy, the uterus and ovaries should appear normal on gross examination. The foci of malignancies in these organs, if present should have the appearance of metastasis or as independent primaries by virtue of their size and distribution.⁴ Histologically most of these are adenocarcinomas. Primary transitional cell carcinoma (TCC) accounts for about 10% of primary tubal carcinomas.¹ Thus Transitional cell carcinoma of the fallopian tube is a very rare histological variant, with only around 20 cases having been reported worldwide so far.^{2,3}

PFTC is more commonly seen in postmenopausal women, but it is not clear whether the same is true about primary transitional carcinoma. Patients with PFTC appear to have a shorter history of symptoms compared to those with epithelial ovarian cancer (PEOC). About 50% to 60% of patients present with vaginal bleeding or spotting, abdominal and/or pelvic mass; and 30% to 40% of patients present with colicky or dull abdominal pain.⁵ Latzke triad of symptoms, consisting of intermittent profuse serosanguinous vaginal discharge, abdominal and/or pelvic pain, is reported in 15% of cases. Grossly, the tubal lumen is usually filled and dilated by papillary or solid and necrotic tumor. The morphology of transitional carcinoma is similar to that of tumors of the urothelium.

There is a newly recognized entity known as parafallopian tube carcinoma, where the tumor is closely attached to the extraluminal portion of the tube. It is presumed to arise from Walthard's rest, paratubal cyst or directly from the tubal serosa.⁶ Hence it is important to distinguish PTCC of fallopian tube from parafallopian tube transitional cell carcinoma to identify any difference in clinical characteristics.

Between 0% and 23% of cases of PFTC may have abnormal cervical cytology suggestive of adenocarcinoma.⁵ Pap smear was negative in the present case as well. There is an isolated case report of transitional cell carcinoma of the fallopian tube diagnosed after a total abdominal hysterectomy with salpingo-oophorectomy done for repeated Pap smear reports suggestive of squamous cell carcinoma.²

The reported rate of preoperative diagnosis in fallopian tube carcinoma is low. Baekelandt et al, have reported a preoperative diagnosis rate of 2%.⁷ Both the USG and the CT scan could not suggest a diagnosis of PFTC in this case because the ovary on the left side was not seen separately from the adnexal mass. However, markedly elevated CA-125 level was strongly suggestive of malignancy in the present case. The pretreatment CA-125 level is an independent prognostic factor of disease-free survival and overall survival in patients with PFTC. CA-125 is also found to be a good marker for post-treatment follow-up, similar to ovarian carcinoma.⁵

Surgery is the treatment of choice, as in cases of ovarian tumors. A staging laparotomy through a generous midline vertical incision is recommended, as in cases of ovarian cancer. Studies suggest that patients with PFTC have higher rates of retroperitoneal and distant nodal metastases than those with epithelial ovarian cancer.⁸ Hence a systematic pelvic and para-aortic lymphadenectomy is preferred to selective lymph node sampling.

Patients with stage I disease without risk factors like involvement of the muscularis layer were reported to have 100% 5-year survival and need not be treated with adjuvant chemotherapy. In contrast, stage I with invasion of the muscularis layer or tumor in the fimbria and higher stages

should receive adjuvant chemotherapy.^{8,9} Adjuvant chemotherapy with a combination of carboplatin and paclitaxel, which is the gold standard of chemotherapy in epithelial ovarian cancer, is now increasingly being used in PFTC.¹⁰ Our literature search did not reveal any report of conservative management in the form of unilateral salpingectomy or salpingo-oophorectomy for early-stage PTCC of the fallopian tube.

Uehira et al, in a study comparing transitional cell (TC)-predominant PFTC with non-TC-predominant PFTC found that TC-predominant tumors tended to relapse later (mean, 31.2 months after diagnosis) than non-TC-predominant tumors (mean, 14.4 months after diagnosis), resulting in a significant difference in the 2-year disease-free survival rate. Hence he concluded that TC pattern and non-TC pattern are considered to be worthy of distinction in PFTC.¹¹

References:

1. Kim JW, Cho EM, Kim YT, Han JH: A case of primary transitional cell carcinoma of the fallopian tube. *J Obstet Gynaecol Res* 1999;25:321-326.
2. Gupta N, Srinivasan R, Nijhawan R, Dhaliwal LK. Primary fallopian tube carcinoma with exfoliation of malignant cells in cervical pap smear. *Cytojournal* 2005;2:20.
3. Park JS, Chang KH, Byun JG, Lee JP, Ryu HS, Han JH. A case of primary transitional cell carcinoma of the fallopian tube. *Korean J Obstet Gynecol* 2005;48:1351-1357.
4. Rose PG, Piver MS, Tsukada Y. Fallopian tube cancer: The Rosewall park experience. *Cancer* 1990 ;66:2661-2667.
5. Pectasides D, Pectasides E, Economopoulos T. Fallopian tube carcinoma: A review. *Oncologist* 2006;11:902-912.
6. Paner GP, Gonzalez M, Al-Masri H, Smith DM, Husain AN. Parafallopian tube transitional cell carcinoma. *Gynecol Oncol* 2002;86:379-383.
7. Baekelandt M, Kockx M, Wesling F, Gerris J. Primary adenocarcinoma of the fallopian tube. Review of literature. *Int J Gynecol Cancer* 1993;3:65-371.
8. Maxson WZ, Stehman FB, Ulbright TM, Sutton GP, Ehrlich CE. Primary carcinoma of the fallopian tube: Evidence for activity of cisplatin combination therapy. *Gynecol Oncol* 1987;26:305-313.
9. Alvarado-Cabrero I, Young RH, Vamvakas EC, Scully RE. Carcinoma of the fallopian tube: A clinicopathological study of 105 cases with observations on staging and prognostic factors. *Gynecol Oncol* 1999;72:367-379.
10. Gemignani ML, Hensley ML, Cohen R, Venkatraman E, Saigo PE, Barakat RR. Paclitaxel-based chemotherapy in carcinoma of the fallopian tube. *Gynecol Oncol* 2001;80:16-20.
11. Uehira K, Hashimoto H, Tsuneyoshi M, Enjoji M. Transitional cell carcinoma pattern in primary carcinoma of the fallopian tube. *Cancer* 1993;72:2447-2456.