



**Case Report:**

**GIST- A Rare Tumor in Paediatric Age Group**

**Kulwant Singh Ded**, Professor and Head, Dept. of Surgery,

**Mandeep Singh Khurana**, Assistant Professor, Dept. of Paediatrics,

**Gursharn Singh Narang**, Professor, Dept. of Paediatrics

**Arun Kumar Gupta**, Assistant Professor, Dept. of Surgery,

**Loveleen Kaur**, Junior Resident, Dept. of Paediatrics,

**Sri Guru Ramdas Institute of Medical Sciences and Research, Vallah, Amritsar.**

**Address for Correspondence:**

**Dr. Gursharn Singh Narang,**

Professor,

Dept. of Paediatrics

Sri Guru Ramdas Institute of Medical Sciences and Research,

Vallah, Amritsar.

**E-mail:** gsnarang321@gmail.com

**Citation:** Ded KS, Khurana MS, Narang GS, Gupta AK, Kaur L. GIST- A Rare Tumor in Paediatric Age Group. *Online J Health Allied Scs.* 2012;11(1):15

**URL:** <http://www.ojhas.org/issue41/2012-1-15.htm>

**Open Access Archives:** <http://cogprints.org/view/subjects/OJHAS.html> and <http://openmed.nic.in/view/subjects/ojhas.html>

Submitted: Feb 23, 2012; Accepted: Mar 22, 2012; Published: Apr 15, 2012

**Abstract:** A 13 years old male child presented to us with complaints of pain abdomen, radiating towards back. Child underwent CT-abdomen with contrast which showed volvulus and child was operated immediately and resected part of gut was sent for histopathology examination. Histopathology report showed features suggestive of gastrointestinal stromal tumour and tumour marker CD-117 was sent for confirmation and report was found to be positive.

**Key Words:** GIST; Mesenchymal tumor.

**Case Report:**

A 13 years old child presented to us with complaints of pain abdomen since last 4 days which was insidious in onset progressive in nature. Pain abdomen was severe, generalised and radiating towards back. There was no history of any aggravating or relieving factors. History of vomiting was present, around 3-4 episodes, which was bilious in nature, non projectile. There was history of non passage of stools since last 5 days. History of associated loss of appetite and loss of weight was present. Child was previously admitted twice with similar complaints, one and half years before and again 6 months before the present admission and child was managed conservatively with IV medications.

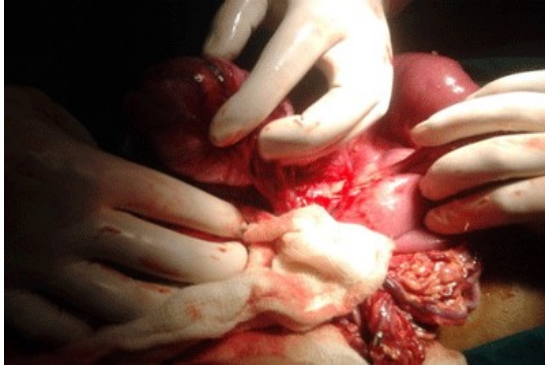
On examination, child was undernourished weighing 30kg. The child had tachycardia and the blood pressure was within normal limits. On abdominal examination, guarding and rigidity was present and severe tenderness was present throughout abdomen. There was a vague mass palpable around umbilical area with irregular border. Child had dark green aspirate through nasogastric tube. X ray abdomen erect was done which showed features of obstruction. Ultrasonography abdomen showed intraperitoneal mass with mesenteric lymphadenopathy and aperistaltic gut loops with thickened walls. Contrast CT abdomen showed features suggestive of malrotation with midgut volvulus with occlusion of distal superior mesenteric artery and superior mesenteric vein with sub mucosal edema of gut loops with massive ascites. Child was taken up for surgery immediately. Intra-operatively a mass was found in the mesentery of jejunum, about 8x8 cm in size. The mass was 1.5ft from duodeno-jejunal junction with malrotation of gut with gangrenous portion of jejunum and enlarged lymph node in mesentery. Excision of Ladd's band, with resection of about 15cm of jejunum and je-

juno-jejunal anastomosis along with excision of mass was done. Appendicectomy was also done. Post operatively, Ryle's tube aspirate was persistently green coloured and pelvic drain had bloody drainage for around 5 days. On 6th post operative day child had massive dark green aspirate and greenish drainage from pelvic drain site. Observing the dark green drainage, child was taken up for surgery again at 8th post operative day. Multiple perforations, about 19 in number, were found. Jejunoleal anastomosis was done and massive gut resection (about 60 cms) was done. Child was given multiple blood and FFP transfusions during post operative period. At around 12th post operative day of 2nd surgery child developed faecal fistula which was of low output type. Gradually fistula output was decreased and patient was sent on oral feed. The histopathology report of the mass in mesentery of jejunum showed appearances suggestive of gastrointestinal stromal tumor and tumor marker CD-117 was advised which was found to be positive.

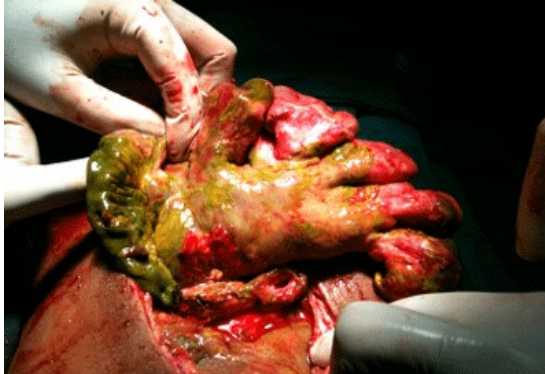**Discussion:**

Gastrointestinal stromal tumors (GISTs) belong to a group of cancers called soft tissue sarcomas. Although the exact incidence is still somewhat unclear, it is now estimated that, in the United States, between 5,000 and 10,000 people each year develop GISTs. GISTs occurring in young patients (under age 18) is much rarer, occurring in perhaps 1% to 2% of all GIST patients.[1,2] GISTs having a first occurrence in patients less than 18 years of age are now described as Pediatric GISTs. Pediatric GIST is much more common in girls than in boys. It usually occurs between the ages of about 6 and 18. GISTs can also originate in the mesentery and omentum. These tumors have been reported ranging in size from smaller than 1 cm to as large as 40 cm in diameter. GISTs can occur anywhere along the gastrointestinal tract, including stomach (70%), small intestine (20-30%), anorectum (7%), colon, and esophagus.[3] Presenting signs and symptoms are variable depending on the size and anatomic location of the tumour and can include abdominal pain, hematemesis, melena, and anemia from occult gastrointestinal bleeding.[4] Other symptoms are generally associated with an enlarging abdominal mass and may include anorexia, nausea, vomiting, weight loss, epigastric fullness, and early satiety. No risk factors have been identified.[5] CD117 has become a very important tool in the differentiation of GIST from other GI mesenchymal tumors.[6,7] Despite the proven

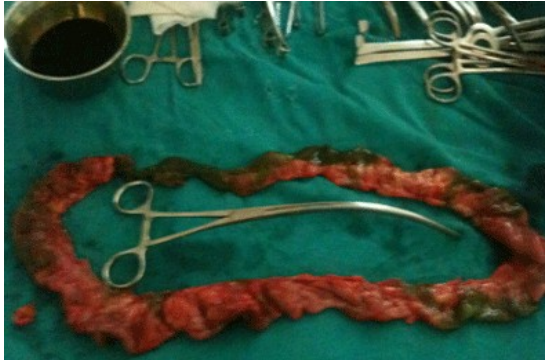success of imatinib and other newer tyrosine-kinase inhibitors, surgical resection remains the treatment of choice and offers the only chance for cure from GIST.[8-10] The main operative principle is resection of the tumor with negative microscopic margins. Our case was a male child of 14 years with this rare tumor who underwent its surgical removal.



**Photograph 1: Mass in mesentery of jejunum, about 8x8 cms**



**Photograph 2: Multiple perforations and gangrenous gut**



**Photograph 3: Massive gut resection, about 60 cms**

#### References:

1. Prakash S, Sarran L, Soggi N et al. Gastrointestinal Stromal Tumors in Children and Young Adults: A Clinicopathologic, Molecular, and Genomic Study of 15 Cases and Review of the Literature. *J Pediatr Hematol Oncol*. April 2005;27:4:179-187.
2. Miettinen M, Lasota J, Sobin LH. Gastrointestinal Stromal Tumors of the Stomach in Children and Young Adults: A Clinicopathologic, Immunohistochemical, and Molecular Genetic Study of 44 Cases With Long-Term Follow-Up and Review of the Literature. *Am J Surg Pathol* October 2005;29(10):1373-1381
3. Park J, Rubinas TC, Fordham LA, Phillips JD. Multifocal gastrointestinal stromal tumor (GIST) of the stomach in a 11-year-old girl. *Pediatr Radiol*. 2006;36:1212-1214.
4. Hayashi Y, Okazaki T, Yamataka A, Yanai T, Yamashiro Y, Tsurumaru M. Gastrointestinal stromal tumor in a child and review of the literature. *Pediatr Surg Int*. 2005;21:914-917.
5. Blanke C, Eisenberg BL, Heinrich M. Epidemiology of GIST. *Am J Gastroenterol*. Oct 2005;100(10):2366.
6. Franquemont DW. Differentiation and risk assessment of gastrointestinal stromal tumors. *Am J Clin Pathol*. Jan 1995;103(1):41-47.
7. Tzen CY, Mau BL. Analysis of CD117-negative gastrointestinal stromal tumors. *World J Gastroenterol*. Feb 21 2005;11(7):1052-1055.
8. Boni L, Benevento A, Dionigi G, Rovera F, Dionigi R. Surgical resection for gastrointestinal stromal tumors (GIST): experience on 25 patients. *World J Surg Oncol*. 2005;3:78.
9. Bucher P, Egger JF, Gervaz P, Ris F, Weintraub D, Villiger P. An audit of surgical management of gastrointestinal stromal tumours (GIST). *Eur J Surg Oncol*. Apr 2006;32(3):310-314.
10. Knoop M, St Friedrichs K, Dierschke J. Surgical management of gastrointestinal stromal tumors of the stomach. *Langenbecks Arch Surg*. Apr 2000;385(3):194-198.