



Case Report:

Renal Cell Carcinoma Presenting as Metastasis to Scrotum and Spermatic Cord

Prashant Panda, Senior Resident, Department of Medicine,

Sanjiv Sharma, Professor, Department of Radiodiagnosis,

UK Chandel, Associate Professor, Department of Surgery,

KS Jaswal, Professor, Department of Surgery

Anupam Jhobta, Associate Professor, Department of Radiodiagnosis

Vikas Bhatia, Senior Resident, Department of Radiodiagnosis

Indira Gandhi Medical College, Shimla.

Address for Correspondence:

Dr. Vikas Bhatia,

Senior Resident,

Department of Radiodiagnosis

Indira Gandhi Medical College,

Shimla.

E-mail: drvikasbhatia@gmail.com

Citation: Panda P, Sharma S, Chandel UK, Jaswal KS, Jhobta A, Bhatia V. Renal Cell Carcinoma Presenting as Metastasis to Scrotum and Spermatic Cord. *Online J Health Allied Scs.* 2012;11(1):21

URL: <http://www.ojhas.org/issue41/2012-1-21.htm>

Open Access Archives: <http://cogprints.org/view/subjects/OJHAS.html> and <http://openmed.nic.in/view/subjects/ojhas.html>

Submitted: Mar 25, 2012; Accepted: Mar 29, 2012; Published: Apr 15, 2012

Abstract: Unusual site metastasis as presenting complaint of renal cell carcinoma (RCC) has been reported previously in literature. RCC is a notorious tumor with unpredictable behavior. We present a case of RCC who presented with scrotal mass and on subsequent investigation was found to have metastasis to scrotum and spermatic cord. Both testis were normal with no evidence of metastasis.

Key Words: Renal cell carcinoma; Metastasis; Spermatic cord.

Introduction:

RCC is a notorious tumor with variable clinical presentation. It is not uncommon that presenting complaints can be unusual and not related to primary tumor. The advent of sophisticated imaging modalities has resulted in a significant increase in the incidental detection of kidney tumors.

Case Report:

We present the report of a 56 years old man who presented with chief complaint of swelling in the left side of scrotum for 2 years. Initially it was stable in size but patient noted increase in size for 2 months duration. There was also evidence of tenderness and pain for the same period. There was evidence of ulceration and bleeding from the swelling for one week. There was no history of any trauma. Patient also complained of generalized weakness and loss of weight for past 3 months. On examination, swelling was present in left scrotal region measuring approx 6x5 cm extending to the left inguinal region. There was ulceration present in the lateral aspect of the swelling. Bilateral testes were palpable separately. Penis was normal. Multiple lymph nodes were palpable in left inguinal region. Patient was thought to have testicular tumor and CECT abdomen and pelvis was requested to rule out retroperitoneal metastasis prior to surgery. On CECT there was evidence of a heterogeneously enhancing mass of size approximately 11x 8.5 x 6 cm present in left renal region. This mass showed no evidence of calcification. There was extension into the anterior pararenal space with loss of fat planes with pancreas. There was evidence of tumor thrombus into the left renal vein. Another large heterogenous mass was seen involving the scrotal sac with extension into the inguinal region. Both testes were seen displaced by the scrotal mass. Pa-

tient was subjected to FNAC from scrotal mass which showed metastatic deposits suggestive of RCC. He then underwent bilateral high orchidectomy. Pathology analysis revealed growth covered by fibrocollagenous tissue on the outside comprised of nests, tubules, with occasional papillae formation separated by thin fibrous stroma having polygonal cells. There were occasional areas of haemorrhage and necrosis. There was infiltration into the left spermatic cord. No evidence of invasion into the testis was seen. Patient then underwent left radical nephrectomy and histopathology revealed clear cell carcinoma. He was referred for chemotherapy.

Discussion:

RCC is notorious for its unpredictable clinical behaviour. Metastatic deposits to the unusual sites is widely described in literature.[1] Metastatic dissemination can affect a large number of organs usually spared from cancer colonization. The interval between primary diagnosis and the occurrence of distant metastasis can vary from metachronous to very long.[2] About one third of the patients with RCC show metastatic disease at the time of diagnosis, and as many as 40% of the other two thirds eventually will develop distant metastasis. The most common site of distant metastases is the lung. Liver, bone, ipsilateral adjacent lymph nodes, adrenal gland, and the opposite kidney are the other frequent sites of metastases. [3] Very rarely metastatic RCC involving the spermatic cord or penis may be seen. The possible mechanisms of spread have been described in literature with retrograde spermatic vein flow described as the most likely course for a left sided tumour. Metastases to the penis have been proposed to occur by direct extension, arterial emboli, retrograde spread via lymphatics, or venous retrograde flow.[4] Skin is a rare site of metastasis compared to other organs and has been reported in about 6%. Cutaneous metastasis of RCC implies poor prognosis.[5] Metastatic tumor of the spermatic cord from RCC usually presents as a painless mass or swelling. Only a few cases of metastasis into the spermatic cord from RCC are reported in the literature.[6,7]

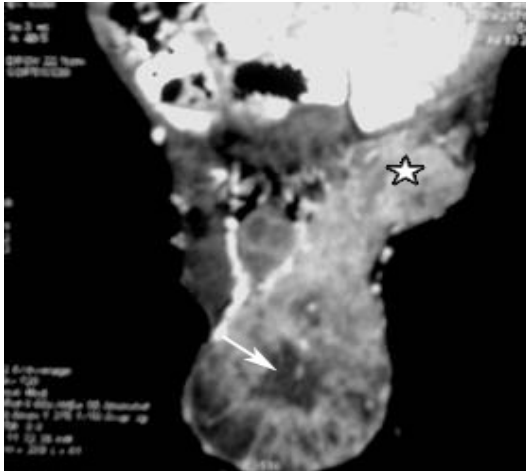
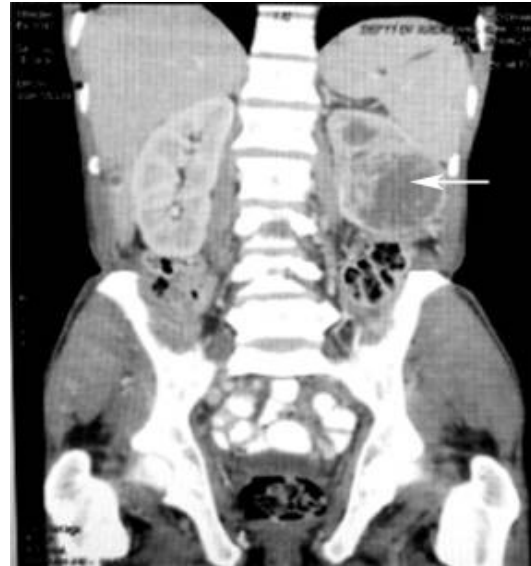


Fig 1a: Coronal CECT image showing heterogeneous mass in left scrotal region (arrow) with extension along the left inguinal region (star).

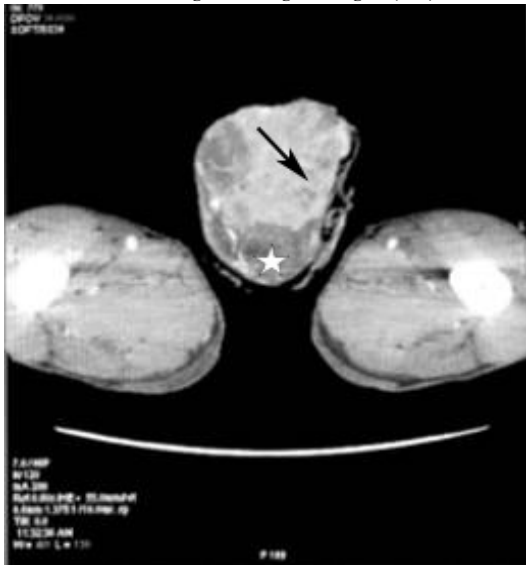
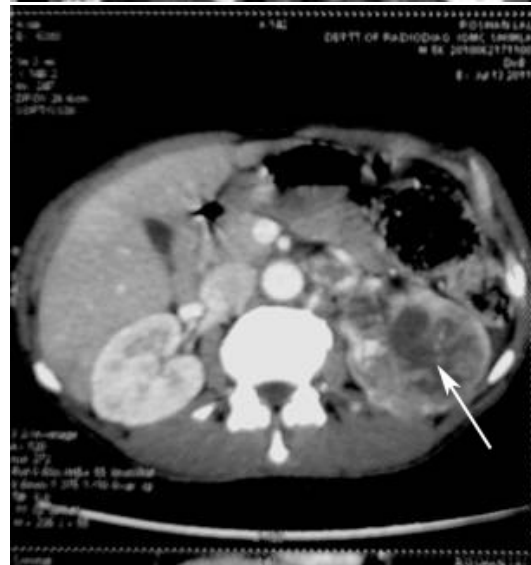
Fig 1b: Axial CECT image showing heterogeneous mass in scrotum (arrow) with posteriorly displaced testis (star).



Figs 2a and 2b: Coronal and axial CECT showing heterogeneous mass in left kidney (arrows)

References:

1. Camerini A, Tartarelli G, Martini L, Donati S, Puccinelli P, Amoroso D. Ipsilateral right testicular metastasis from renal cell carcinoma in a responder patient to interleukine-2 treatment. *International Journal of Urology* 2007;14:259–260.
2. Gogus C, Kilic O, Tulunay O, Tulunay O, Beduk Y. Solitary metastasis of renal cell carcinoma to the parotid gland 10 years after radical nephrectomy. *Int. J. Urol.* 2004;11:894–896.
3. Novick AC, Campbell SC. Renal Tumors. In: Walsh PC, Retik AB, Vaughan ED Jr, Wein AJ. (eds.). *Campbell's Urology*, 8th Edition. Philadelphia, Saunders, 2002. pp. 2672–2731.
4. Daniels GF Jr, Schaeffer AJ. Renal cell carcinoma involving penis and testis: Unusual initial presentations of metastatic disease. *Urology* 1991;37:369–373.
5. Williams JC, Heaney JA. Metastatic renal cell carcinoma presenting as a skin nodule : case report and review of the literature. *J Urol.* 1994;152:2094–2095.
6. Viswaroop SB, Gopalakrishnan G. Isolated Metastasis of Renal Cell Carcinoma into the Spermatic Cord. *Kuwait Medical Journal* 2004;36(3):199–200.
7. Sountoulides P, Metaxa L, Cindolo L. Atypical presentations and rare metastatic sites of renal cell carcinoma: a review of case reports. *Journal of Medical Case Reports* 2011;5:429.