



Case Report

Struma Ovarii Associated with Pseudo- Meigs' Syndrome

Authors

Sushma Rajesh Gulhane, Assistant Professor, Department of Pathology, ESI-PGIMS, Mumbai-93,
Riti Tusharkanti Sinha, Consultant Pathologist, Department of Pathology, NTPC Hospital, Farraka, West Bengal,
Gangane NM, Professor & Head, Department of Pathology, Mahatma Gandhi Institute of Medical Sciences, Sevagram, Wardha.

Address for Correspondence

Dr. Sushma R. Gulhane

Quarter No. 12, ESIC Model Hospital staff,
Andheri (E), Mumbai-93.

E-mail: drsushmagulhane76@gmail.com

Citation

Gulhane SR, Sinha RT, Gangane NM. Struma ovarii associated with Pseudo- Meigs' syndrome. *Online J Health Allied Scs.* 2012;11(2):10. Available at URL: <http://www.ojhas.org/issue42/2012-2-10.htm>

Open Access Archives

<http://cogprints.org/view/subjects/OJHAS.html>

<http://openmed.nic.in/view/subjects/ojhas.html>

Submitted: Apr 10, 2012; Accepted: Jun 30, 2012; Published: Jul 25, 2012

Abstract: Struma ovarii is a specialized ovarian teratoma composed predominantly of mature thyroid tissue. It is associated with pleural effusion and ascites (Pseudo-Meigs' syndrome) in 5% of cases. Majorities of the strumas are benign, however occasionally malignant transformation may be seen. We report a case of a 45 years old postmenopausal woman who presented with gradually increasing dyspnoea and distention of abdomen of five months duration. USG abdomen revealed a bulky right ovary with a solid and cystic components and ascites. Her chest X-ray showed bilateral pleural effusion. Hence, clinical diagnosis of malignant ovarian tumor was kept; however, both the ascitic & pleural fluids were cytologically negative for malignant cells. The patient was operated for hysterectomy with bilateral salpingo-oophorectomy. The histopathological examination of the ovarian mass confirmed the diagnosis of struma ovarii. Postsurgical follow up of patient showed spontaneous regression of pleural effusion and ascites. The coexistence of an ovarian tumor, ascites and bilateral pleural effusion that resolves spontaneously on resection of the ovarian mass is known as pseudo-Meigs' syndrome. Patient with pseudo-Meigs' syndrome may present a diagnostic problem as they masquerade as carcinoma with malignant effusions. In addition, the coexistence of struma ovarii and pseudo-Meigs' syndrome is a very rare event.

Key Words: Struma ovarii; Monodermal teratoma; Ovarian tumor; Pseudo-Meigs' syndrome

Introduction:

Introduction

Monodermal teratoma is a rare ovarian tumor showing the presence of only single type of cellular component. A monodermal teratoma showing presence of more than 50% areas only thyroid tissue as a major cellular component is known as struma ovarii.¹ It is the most common type of monodermal teratoma and accounts for 2.7% of all the ovarian teratomas.² Mostly these are benign tumors and very rarely

malignant variant may occur representing 0.01% of all ovarian tumors and 5-37% of all struma ovarii.³ It is necessary to differentiate struma ovarii from those 10% of the teratomas that contain an occasional focus of thyroid tissue. The concomitant presence of pseudo-Meigs' syndrome with struma ovarii is a rare occurrence. Nevertheless, this syndrome must be considered in otherwise healthy postmenopausal women, who present with both new or recurrent hydrothorax and ascites as it may masquerade the ovarian malignancy.⁴

Case Report

A 45-year-old postmenopausal woman presented with the complaints of pain and distention of abdomen since five months. She also complained of increasing breathlessness over the past two months. On per abdomen examination, ascites was present and on per vaginal examination, there was fullness in the right fornix. Ultrasonography of the abdomen and pelvis revealed the presence of a bulky right ovary with solid and cystic components; features suggestive of ovarian malignancy with ascites (Fig.1). Radiograph of the chest was done in view of dyspnoea that showed the presence of bilateral pleural effusion, which was otherwise unremarkable (Fig.2). All the biochemical investigations were within normal limits. The cytological examination of the ascitic and pleural fluid revealed the presence of reactive hyperplastic mesothelial cells, malignant cells were not seen; hence, the diagnosis of non-inflammatory serous effusion was offered. On exploratory laparotomy, a right ovarian tumor was found with ascites.

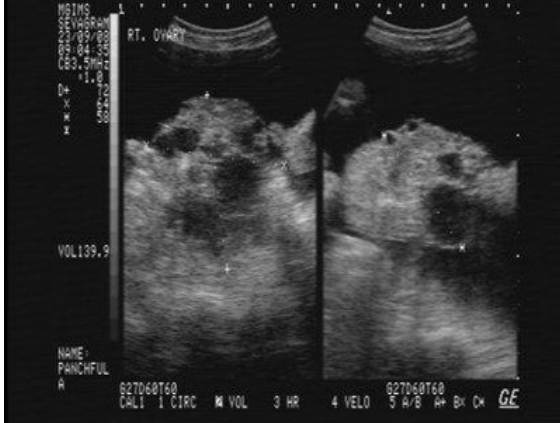


Fig 1: Ultrasonography of the abdomen and pelvis showing a cystic right ovarian mass with ascites

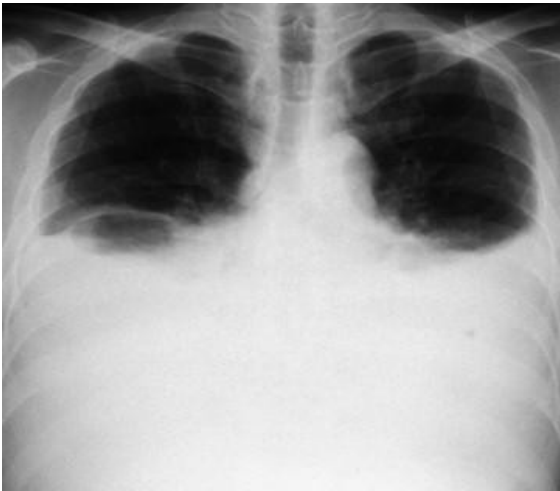

Fig 2: Radiograph of the chest was showing bilateral pleural effusion

We received a specimen of hysterectomy with bilateral salpingoophorectomy. The right ovarian mass was partially cystic and solid in consistency and measured 7x5x3.5 cm. On cut surface, it showed a multicystic appearance with few solid areas. The cysts contained thick brownish colloid like fluid. The specimen was extensively sampled. Sections were fixed in 10% buffered formalin and processed as per the routine protocol for histopathology sections.

The microscopic examinations showed the tumor to be surrounded by a rim of normal ovarian tissue (Fig.3). The tumor composed of follicles lined by flattened follicular cells and filled with homogeneous eosinophilic material, which was confirmed to be colloid on Periodic Acid Schiff's (PAS) staining (PAS positive colloid). At occasional places the follicles were densely packed with the nuclei showing slightly opened up chromatin (Fig 4). Features suggestive of malignancy e.g. invasion of stroma, blood vessels, capsule were not seen. Hence, the diagnosis of a monodermal teratoma-struma ovarii was entertained. On considering the clinical presentation of the patient i.e. hydrothorax, ascites and a benign ovarian tumor other than a fibroma, it was found to be a rare association of pseudo-Meigs' syndrome with struma ovarii.

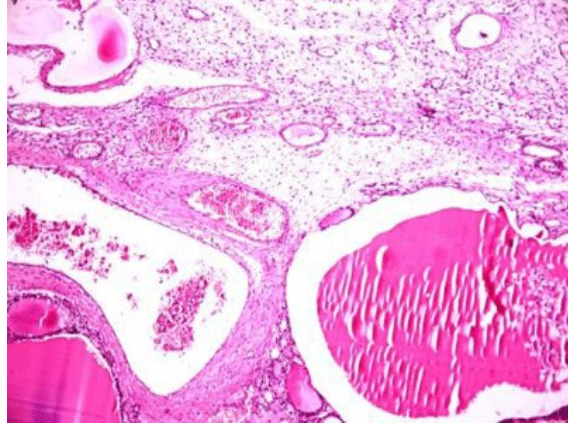


Fig 3: Photomicrograph of struma ovarii showing a thin rim of normal ovarian tissue (H&E 400X)

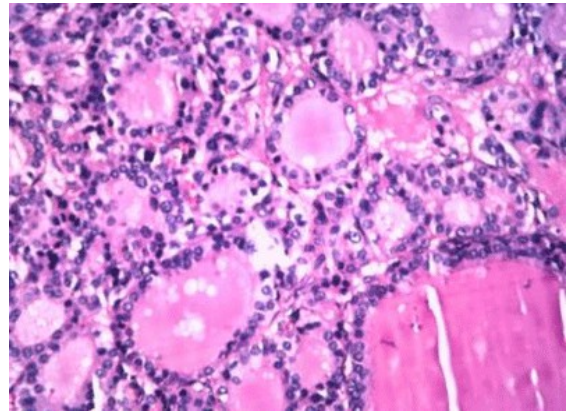


Fig 4: Photomicrograph of ovarian mass showing densely packed follicles filled with colloid and opened up chromatin in the nuclei (H&E 400X)

Discussion

The coexistence of pelvic tumor, hydrothorax and ascites has been known since the late 19th century. Meigs' and Cass described the features of the disease in 1937 and this was named as "Meigs' syndrome" by Roads in the same year.⁵ Today, Meigs' syndrome is defined as the triad of benign ovarian fibroma, hydrothorax, and ascites, which resolves spontaneously on the resection of the ovarian tumor. Whereas, Pseudo-Meigs' syndrome is the co existence of hydrothorax, ascites and other ovarian tumor or pelvic tumors.⁴ The association of pseudo-Meigs' syndrome to the struma ovarii is a rare condition. So far only 9 to 10 cases have been reported in English literature through MEDLINE search.²

The etiology of fluid accumulation in pseudo-Meigs' syndrome remains unclear, though it appears to be related to the lymphatic obstruction. The most probable pathogenesis of the peritoneal and pleural effusions is ascribed to filtration of interstitial fluid in the peritoneum through the tumor capsule and diffusion to the pleural space, though the diaphragmatic lymphatic vessels and apertures covered with loose areolar tissue. These effusions are derived from a transudative process & regress spontaneously after the removal of the neoplasm.⁶ However, the detection of malignant cells in ascitic/pleural fluid is a marker of metastatic disease and is a sign of bad prognosis, benign effusions of pseudo-Meigs' syndrome affects neither the disease stage nor the patients' prognosis.²

Ascites may be present in up to one-third of the cases of struma ovarii. However, the association of ascites and pleural effusion with this tumor is uncommon.¹ Pleural effusion and ascites is known to be associated with an ovarian fibroma/thecoma, a

condition originally described by Meigs' in 1937. When the same clinical features exist but involve other ovarian or gynecological tumors, it is referred to as pseudo-Meigs' syndrome. Struma ovarii rarely presents as pseudo-Meigs' syndrome in about 5% of the cases.^{4,7} The struma ovarii may also be associated with other ovarian neoplasms like Brenner's tumor, serous cystadenoma, mucinous cystadenoma and melanoma [Table 1].⁸

Benign tumors	Malignant tumors
1. <i>Ovarian tumors, other than fibromas - Struma ovarii, Stromal tumors, Teratomas, Cystadenomas</i>	1. <i>Primary ovarian tumors - Adenocarcinoma, Endometrioid carcinomas</i>
2. <i>Uterine leiomyomas</i>	2. <i>Secondary metastatic ovarian tumors from primary gastrointestinal cancers</i>
3. <i>Leiomyomas of broad ligament</i>	

First described by Boettlin in 1899 Struma ovarii is a special type of monodermal teratoma, defined as a mature teratoma composed either exclusively or predominantly of thyroid tissue.⁹ It occurs most commonly around the fifth decade of life. Cases are reported equally amongst nulliparous and multiparous women. The thyroid tissue present in this ovarian neoplasm is chemically, biologically and microscopically identical to the cervical thyroid tissue.¹⁰ It is necessary to differentiate struma ovarii from the 10% of those teratomas that contain an occasional focus of thyroid tissue.

The incidence of struma ovarii varies in different studies. In a recent review of 282 ovarian tumors, two cases of struma ovarii have been reported.¹⁰ The tumor usually occurs as a pelvic mass that may be palpable on physical examination. Most of the cases are incidentally diagnosed during clinical and imaging examination, as was in our case.

The struma ovarii on gross usually present as unilateral mass measuring 0.5-10 cms in diameter. It has a brown, solid, gelatinous sectioned surface with colloid filled cysts that are characteristic. Rarely the contralateral ovary may contain a dermoid cyst or even a struma. On microscopic examination, it is composed of mature thyroid follicles filled with eosinophilic colloid and lined by cuboidal or columnar cells with uniform round nuclei. Degenerative changes such as fibrosis, calcification and aggregates of haemosiderin-laden macrophages can be present.⁶

The signs and symptoms caused by struma ovarii can be due to the presence of the pelvic mass. Patients may present with clinical hyperthyroidism, ascites, pleural effusion, or may be asymptomatic. The tumour may be functional in about 8% of cases and may be associated with enlarged thyroid gland in 10-15% of patients. The surgical removal of the struma in such cases usually results in the resolution of symptoms.⁹

Extensive grossing is required to rule out any other component like neural, cartilage, or skin with adnexal tissue before labeling any ovarian tumor as a monodermal tumor it as monodermal teratoma.⁷

Malignant transformation of the struma ovarii is rare. Ovarian thyroid tissue undergoing malignant change accounts for 0.01% of all ovarian tumours. Most of the cases of malignant struma ovarii have been diagnosed based on histological criteria alone, with only 20 cases presenting clinically appreciable metastasis.¹⁰ Struma ovarii may also harbor changes histologically identical to thyroid adenomas, or be admixed with a carcinoid (strumal carcinoid). The morphology of the thyroid tumors within the struma is similar to that of the ectopic thyroid.

The thyroid tissue undergoes malignant change predominantly to papillary carcinoma.⁶

Simple salpingoophorectomy is the therapy of choice for most cases, as these tumors are mostly unilateral and benign. Total hysterectomy with bilateral salpingoophorectomy is indicated for bilateral tumors or in postmenopausal women. In patients with thyroid involvement, concomitant thyroidectomy has been advocated.

Conclusion

This report emphasizes that there are benign gynaecological conditions might show clinical, ultrasonographic and biochemical signs suggestive of malignancy. They rarely should be considered as the benign diseases in the differential diagnosis when the patients presented with ascites and pleural effusions, but with negative cytological examination. Also the association of pseudo-Meigs' syndrome with struma ovarii is very rare. Hence, the present case turned out to be quite unique and of special interest.

References

1. Szyfelbein WM, Young RH, Scully RE. Struma ovarii simulating ovarian tumors of other types. A report of 30 cases. *Am J Surg Pathol.* 1995;19(1):21–29
2. Wei Jiang, Xin Lu, Zhi Ling Zhu, Xi Shi Liu, and Cong Jian Xu. Struma ovarii associated with pseudo-Meigs' syndrome and elevated serum CA 125: a case report and review of the literature. *J Ovarian Res.* 2010;3:18.
3. Zakhem A, Aftimos G, Kreidy R, Salem P. Malignant struma ovarii: report of two cases and selected review of the literature. *J Surg Oncol* 1990;43: 61–65.
4. Papanikolaou Ch, Fortounis K, Ainalis S, Biba K, Papanikolaou A, Hatzitheoxaris G. Pseudo-Meigs' Syndrome : A Case Report. *The Internet Journal of Pathology.* 2005;4:1528-8307
5. Loizzi V, Cormio G, Resta L, Fattizzi N, Vicino M, Selvaggi L. Pseudo-Meigs' syndrome and elevated CA125 associated with struma ovarii. *Gynecol Oncol* 2005;97:282-284.
6. Zannoni GF, Gallotta V, Legge F, Tarquini E, Scambia G, Ferrandina G. Pseudo-Meigs' syndrome associated with malignant struma ovarii: a case report. *Gynecol Oncol.* 2004;94:226–228.
7. Rana V, Srinivas V, Bandyopadhyay S, Ghosh SK, Singh Y. Bilateral benign non functional struma ovarii with Pseudo-Meigs' syndrome. *Indian J Pathol Microbiol.* 2009;52: 94-96.
8. Paladini D, Vassallo M, Sglavo G, and Nappi C. Struma ovarii associated with hyperthyroidism, elevated CA 125 and pseudo-Meigs' syndrome may mimic advanced ovarian cancer. *Ultrasound in Obstetrics & Gynecology.* 2008;32:237–238.
9. Boettlin R. Struma ovarii. *Virchow's Arch Pathol Anat* 1989;115:493-495.
10. Ganga Pilli S, Suneeta KP, Dhaded AV, Yenni VV. Ovarian tumours: A study of 282 cases. *J Indian Med Assoc* 2002;100:420-424.