



Case Report

A Rare Case of Isolated torsion of Haematosalphinx Presenting as Acute Abdomen During Pregnancy

Authors

Shakuntala PN, Shubha R Rao, Poornima M, Padmalatha VV,
Department of Obstetrics and Gynaecology, St. Martha's Hospital, Bengaluru

Address for Correspondence

Dr. Shakuntala PN,
Department of Obstetrics and Gynaecology. St. Martha's Hospital, Bengaluru
E-mail: shakuntala_pn@yahoo.com

Citation

Shakuntala PN, Rao SR, Poornima M, Padmalatha VV. A Rare Case of Isolated torsion of Haematosalphinx Presenting As Acute Abdomen During Pregnancy. *Online J Health Allied Scs.* 2012;11(2):13. Available at URL:<http://www.ojhas.org/issue42/2012-2-13.htm>

Open Access Archives

<http://cogprints.org/view/subjects/OJHAS.html>
<http://openmed.nic.in/view/subjects/ojhas.html>

Submitted: May 6, 2012; Accepted: Jun 30, 2012; Published: Jul 25, 2012

Abstract: Isolated fallopian tubal torsion is a rare non obstetric cause for pain abdomen during pregnancy. We report a case of a 34 year old second gravida who presented with history of amenorrhoea of 7 months, colicky pain in the left iliac fossa, with 2 episodes of vomiting. A Trans vaginal scan revealed a left ovarian cyst. An emergency laparotomy was performed for suspected torsion or haemorrhage into an ovarian cyst. Surprisingly ovaries were normal and a congested and necrotic left tubal torsion with a tubal collection (haematosalphinx) was identified and a salpingectomy was then performed. The differential diagnosis is discussed and the literature is reviewed as it is a very rare clinical entity.

Key Words: Fallopian tube torsion; Acute abdomen; Pregnancy; Salpingectomy

Introduction

Isolated tubal torsion is a rare event, with an incidence of 1:1,50,000 women.(1) Isolated fallopian tube torsion in pregnancy is also very rare, only 12% of cases are found during this time.(2) The lack of specific symptoms, clinical findings and non-specific imaging or laboratory characteristics makes this entity difficult to diagnose preoperatively, which can cause surgical intervention to be postponed. During the third trimester of pregnancy salvaging the fetus and preventing a preterm birth takes priority over surgical intervention unless indicated. The diagnosis is often difficult and established during the operation. The right fallopian tube is most commonly affected(90%) and the left tubal torsion is even rarer as in the present case.

Differential diagnosis can involve gynaecological and gastrointestinal conditions including torsion and or haemorrhage of an ovarian cyst, red degeneration of subserosal fibroid, chronic tubo-ovarian mass, heterotopic pregnancy, appendicitis, diverticulitis and inflammatory bowel diseases.(3)

We report this rare cause for pain abdomen during pregnancy, which needs a high degree of clinical suspicion, which

can change the management to save the tube and future fertility by early intervention. To date, it is the 22nd case of isolated tubal torsion during pregnancy and third case to involve the left tube reported in the English medical literature.(3,4)

Case Report:

A 34 year old second gravid with one living child presented with history of amenorrhoea of 8 months, associated with excruciating left sided pain abdomen, which was colicky and dull aching, restricting her daily activities, with 2-3 episodes of vomiting and giddiness. The pain was not aggravated by fetal movements but radiated to the left thigh and back. There was no other significant history. On examination, except for grade I pedal edema and blood pressure on the higher range, antihypertensive medication was started. On per abdominal examination, uterus corresponded to 30 weeks of pregnancy with single live intrauterine gestation in longitudinal lie in cephalic presentation, with clinically adequate liquor volume, appreciable fetal movements and normal fetal heart sounds. Rebound tenderness was felt in the left iliac fossa. Since she had pain abdomen and decision was pending, a per speculum examination performed revealed absence of leaking per vaginum and a closed external os excluding impending preterm labour. Per vaginal examination was not contributory, other than tenderness in the left adnexa. Laboratory parameters other than leucocytosis with increased total count were normal. A transvaginal scan reported the possibility of a left ovarian cyst measuring 7x7x7 centimeters with a volume of 140 ml, with minimal internal echoes and no septations. Hence we scaled down to a diagnosis of left ovarian cyst, with a possibility of torsion of ovary or red degeneration of a subserosal fibroid. She received two doses of betnasol 24 hours apart to enhance fetal lung maturity. After almost 30 hours of admission she became febrile, had episodes of vomiting, and severe abdominal pain, hence we performed an emergency laparotomy.

During surgery minimal haemorrhagic fluid was seen in the abdominal cavity, after lateralizing the pregnant uterus, a mass

measuring 6x6x6 centimeters, bluish black in colour, tense and cystic to feel was delivered out of the abdominal cavity, surprisingly the ovary appeared normal, the fallopian tube had undergone 3 turns of torsion and looked congested and necrotic with collection in the tube distal to the torsion and the medial side of the tube appeared normal, the fimbrial end was sealed and appeared unhealthy.(Figure1,2) Left salphingectomy was then performed.(Figure-3.)

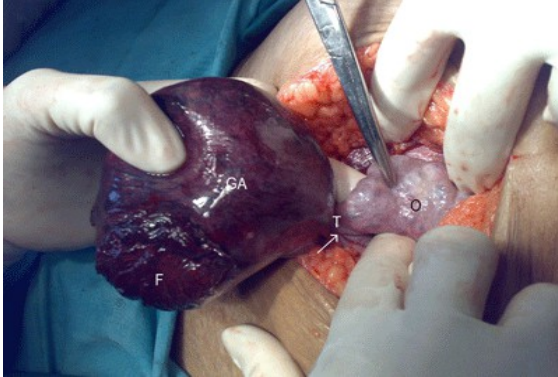


Fig-1: T- left tubal torsion with 3 turns. O-normal looking ovary, GA-congested and gangrenous looking tube lateral to the torsion. F-fimbrial end of the tube appearing blocked, leading to haematosalpinx and torsion.

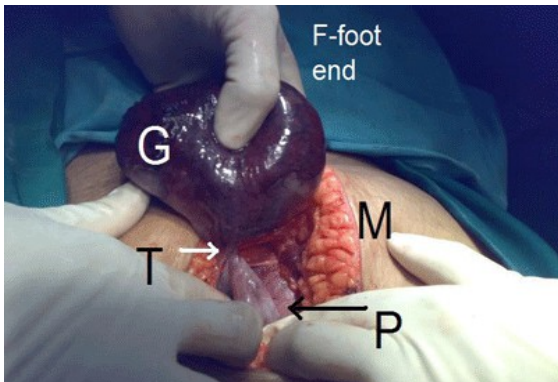


Fig-2: P- Pregnant uterus, M- mid line vertical incision, T-left tubal torsion, G- congested and gangrenous changes in the tube lateral to torsion. FT- foot end of the patient.

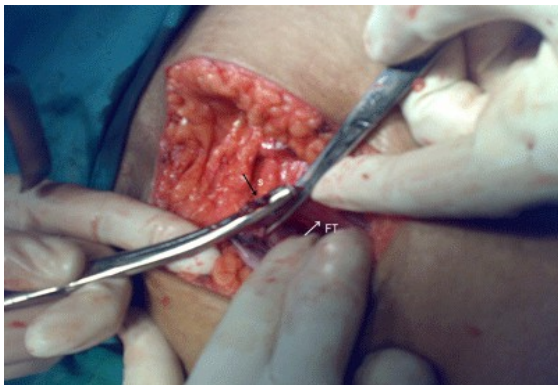

Fig-3: S-Salpingectomy, FT - normal appearing medial end of the tube

Pathology: Grossly the tube with its haemorrhagic contents, measured 9x7.5x2.5 cms. A cut section revealed an unilocular cyst containing blood tinged fluid. The inner lining of the cyst showed whitish areas of necrosis. Microscopically, the cyst

lining was cuboidal to columnar with haemorrhage and necrosis, suggesting a haematosalpinx.

She recovered post operatively and continued her pregnancy and delivered a live male baby weighing 3.4 kilograms at 38 completed weeks of gestation vaginally.

Discussion:

Isolated tubal torsion is a rare gynaecologic cause of acute low abdominal pain, with a reported incidence of 1:1,50,000 women and 12% of these torsions occur during pregnancy.(1,2)

Since there are no specific symptoms or physical signs which pin point to a diagnosis of tubal torsion, ultrasound findings may be non-specific in the setting of a third trimester of pregnancy due to displacement of the adnexal structures and laboratory parameters other than a raised total count and leucocytosis may be normal. About 90% of the times diagnosis is made during the surgical exploration as in the present case.(2,3)

The differential diagnosis considered by us was an ovarian cyst with torsion, possibility of ovarian cyst rupture with intraperitoneal haemorrhage, red degeneration of a subserosal fibroid in the pregnant uterus.

The exact cause for tubal torsion is not known. Youssef et al(5) noted factors that could possibly influence the occurrence of fallopian tube torsion and divided them into two types: internal and external. Tubal ligation, hematosalpinx, congenital hydrosalpinx, and tubal neoplasm are some of the intrinsic causes. Trauma, pregnancy, adhesions, and ovarian tumors are some of the extrinsic causes.(5)

The possible mechanism, begins with the mechanical blockage of the adnexal veins and lymphatic vessels by ovarian tumor, pregnancy, hydrosalpinx and pelvic adhesions after tubal infection, or pelvic operation. This obstruction causes pelvic congestion and local edema, with subsequent enlargement of the adnexa, which in turn induces partial or complete torsion. Furthermore, the mechanical blockage of the distal part of the fallopian tubes, together with the normal secretion of the fallopian tube glands, can cause hydrosalpinx, a risk factor by itself for torsion as in the present case.(5,6) It rarely occurs before menarche or during menopause. This variation may be due to occurrence of ovarian cysts, infections, and pelvic surgery mainly in the reproductive age group.(6)

The most common symptom is lower abdominal pain or a pelvic pain. Pain is usually located in the iliac fossa. There may be radiation to the flank and or thigh. Onset of pain can be either sudden or gradual. Pain duration is usually less than 48 hours. Nausea and vomiting is present in 2/3 of cases as noticed in the present case.(7)

Pelvic examination usually does not reveal any palpable mass, unless ovarian torsion presents. The majority of the time, pelvic ultrasound shows adnexal mass as discussed in the present case. Pelvic ultrasound with color doppler may show changes in flow in the affected tube. CT of the abdomen/pelvis may show cystic structure in the adnexal region.(7)

In cases of tubal torsion with an ischaemic event, the shorter the time from diagnosis to intervention plays an important role to prevent tubal necrosis and gangrenous changes. Very high degree of clinical suspicion is required if a pregnant woman presents with acute lower pain abdomen and hence should be considered in the differential diagnosis of acute lower pain abdomen during pregnancy which can change the management, instead of salpingectomy a detorsion of the tube can be performed leading to fertility preservation in these young women for future child bearing.(8)

But the prime question to be answered is when faced with a dilemmatic condition as in the present case. Pregnant woman in the 30th week of gestation, when the concern is to salvage the present fetus and not all ovarian cysts in pregnancy or a red degeneration of fibroid need an exploration, tubal torsion being a

rare event and was not considered in our differential diagnosis. On exploration we reasoned, either way the unhealthy tube would have been a nidus for future ectopic pregnancy or another episode of torsion and needs removal. If the present pregnancy was carried on successfully, she would be completing her family. Therefore, we are justified in our conservative approach followed by emergency salpingectomy. Similar dilemmatic and successful outcomes have been reported by other authors.(9,10)

Isolated fallopian tubal torsion during pregnancy is a very rare clinical condition. We strongly recommend tubal torsion as a cause for acute pain abdomen during pregnancy and consider it in differential diagnosis. But, stress the need for individualization of treatment depending on the whole scenario of the patient profile and her future needs, as with our patient, we took a chance to wait for the steroids to act on fetus, as salvaging fetus was our priority rather than embarking on an immediate laparotomy to save the ovary or the tube. She had an uneventful vaginal delivery of a live, mature, healthy male baby and completed her family. This successful outcome was worth the wait and excision of the diseased fallopian tube!

References:

1. Hansen OH. Isolated torsion of the Fallopian tube. *Acta Obstet Gynecol Scand* 1970;49:3-6
2. Regad J. Etude Anatomopathologique de la torsion des trompes uterines. *Gynecol Obstet* 1933;27:519-535
3. Işçi H, Güdücü N, Gönenç G, Başgul AY. Isolated tubal torsion in pregnancy-a rare case. *Clin Exp Obstet Gynecol*. 2011;38(3):272-273.
4. Orioni M, Cavoretto P, Cont E, Ferrari A. Isolated tubal torsion in pregnancy. *European Journal of Obstetrics & Gynecology and Reproductive Biology* October 2009;146(2):116-120.
5. Youssef AF, Fayad MM, Shafeek MA. Torsion of the fallopian tube. A clinico-pathological study. *Acta Obstet Gynec Scand* 1962;41:292-309.
6. Krissi H, Shalev J, Bar-Hava I, Langer R, Herman A, Kaplan B. Fallopian tube torsion: laparoscopic evaluation and treatment of a rare gynecological entity. *J Am Board Fam Pract* 2001;14:274-277.
7. Maynard SR, Peipert JF, Brody JM. Tubal torsion appearing as acute pelvic inflammatory disease. *J Am Assoc Gynecol Laparosc* 1996;3:431-433.
8. ten Cate A, Han S, Vliegen AS, Lewi L, Verhaeghe J, Claus F. Conservative surgery for left-sided isolated tubal torsion in pregnancy. *JBR-BTR*. 2011 Jul-Aug;94(4):212-213.
9. Batukan C, Ozgun MT, Turkyilmaz C, Tayyar M. Isolated torsion of the fallopian tube during pregnancy: a case report. *J Reprod Med*. 2007 Aug;52(8):745-747.
10. Yalcin OT, Hassa H, Zeytinoglu S, Isiksoy S. Isolated torsion of fallopian tube during pregnancy; report of two cases. *Eur J Obstet Gynecol Reprod Biol*. 1997 Aug;74(2):179-182.