



Case Report:

Ectopic Prostatic and Seminal Vesicle Tissue Confusing as Metastatic Adenocarcinoma.

Authors

Jyotsna Wader, Ashok Kshirsagar, Neha Gajbi, Sujata Kumbhar,
Department of Pathology, Krishna Institute of Medical Sciences, Karad, Maharashtra, India.

Address for Correspondence

Dr. Neha Gajbi,
Department of Pathology,
Krishna Institute of Medical Sciences,
Karad, Maharashtra, India.
E-mail: dr.komalgajbi@gmail.com

Citation

Wader J, Kshirsagar A, Gajbi N, Kumbhar S. Ectopic Prostatic and Seminal Vesicle Tissue Confusing as Metastatic Adenocarcinoma. *Online J Health Allied Scs.* 2013;12(1):8. Available at URL: <http://www.ojhas.org/issue45/2013-1-8.html>

Open Access Archives

<http://cogprints.org/view/subjects/OJHAS.html>
<http://openmed.nic.in/view/subjects/ojhas.html>

Submitted: Feb 16, 2013; Accepted: Apr 2, 2013; Published: Apr 15, 2013

Abstract: Ectopic prostatic tissue and seminal vesicle at pericolic fat is extremely rare. The nodules in the pericolic fat could raise a dilemma of metastatic deposits in cases of rectal adenocarcinoma. A 61 years old male underwent abdomino-perineal resection for rectal carcinoma. Nodules along with lymph nodes from pericolic fat were sampled to assess the spread. Histopathological and immunohistochemical staining of one nodule confirmed it to be the prostatic tissue while another nodule to be seminal vesicle. Seminal vesicle and prostatic heterotopia is significant in several respects, either symptomatic or asymptomatic, as the ectopic tissue can be endoscopically and histologically confused with malignancy of urinary or lower gastrointestinal system and may reflect divergent differentiation or a malformative process.

Key Words: Ectopic prostate; Seminal vesicle; Adenocarcinoma

Introduction:

Ectopic seminal vesicle and prostatic tissue is an extremely rare finding.^{1,2}

We report a case of ectopic prostatic tissue showing benign prostatic hyperplasia and seminal vesicle in pericolic fat in a 61 years old male operated for rectal carcinoma.

Case Report

A 61 years old male presented with constipation and pain in abdomen to his physician. A digital rectal examination revealed a firm, irregular growth. An ultra sonogram showed evidence of annual distal rectal growth with no signs of large bowel obstruction. Diagnosis of well differentiated adenocarcinoma was made on rectal biopsy and underwent abdominoperineal resection (APR) for rectal carcinoma. No pelvic lymphadenopathy was appreciated, and other pelvic organs were unremarkable.

On gross examination, the specimen revealed an ulceroinfiltrative growth measuring 3 x 2 cm and involving 80% of the circumference. Cut section of the growth revealed gray white tumor infiltrating the entire thickness of the rectum. Five nodules were dissected out from the pericolic

fat. The largest measuring 2.3x1.5x1 cm, cut section is gray white in appearance.

Microscopically, sections from the rectal growth revealed well differentiated adenocarcinoma – Duke's stage IIA.

The largest nodule from pericolic fat revealed benign glands embedded in a fibromuscular stroma. The glands have double layered epithelium comprised of an inner columnar and an outer basal cell layer and shows papillary infoldings – features suggestive of benign prostatic hyperplasia.

The prostatic origin of the tissue was confirmed by immunoperoxidase staining, the glands exhibited strong positivity for prostate specific antigen (PSA) and fibromuscular stroma was positive for smooth muscle actin (SMA). Stains for high molecular weight cytokeratin (34BE12) confirmed the basal layer of epithelium excluding prostatic adenocarcinoma or prostatic intraepithelial neoplasia.

A small nodule was diagnosed histologically to be seminal vesicle with thick muscular wall and highly complex mucosal folds. The epithelial cells revealed large amount of lipofuscin pigment characteristic of seminal vesicle.

The remaining nodules revealed lymph nodes with no evidence of tumor metastasis.

Special attention was paid to find out similarity or dissimilarity between the primary rectal adenocarcinoma and the glandular tissue in the nodule.

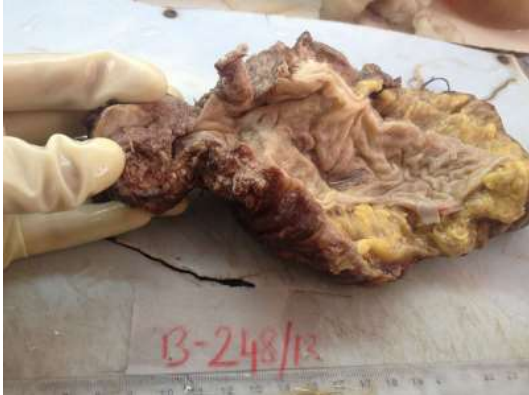

Figure 1: Gross photograph of rectal growth – adenocarcinoma

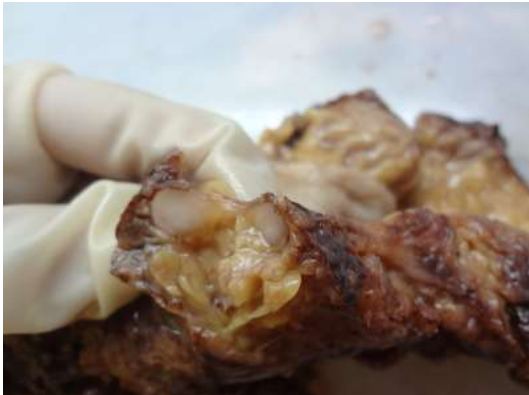

Figure 2 (a) and (b): Gross photograph of nodules in pericolic fat

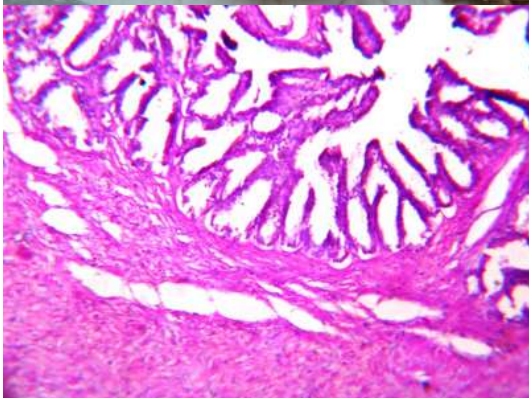
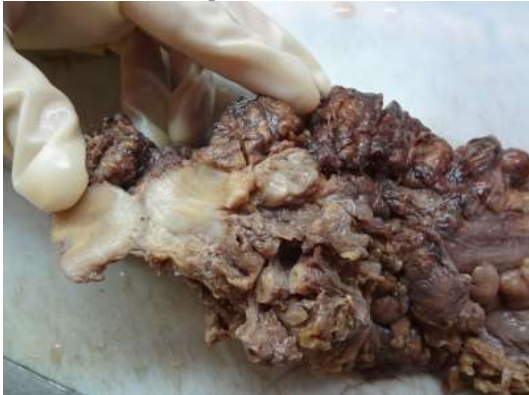

Figure 3: Ectopic seminal vesicle (H & E stain 400x)

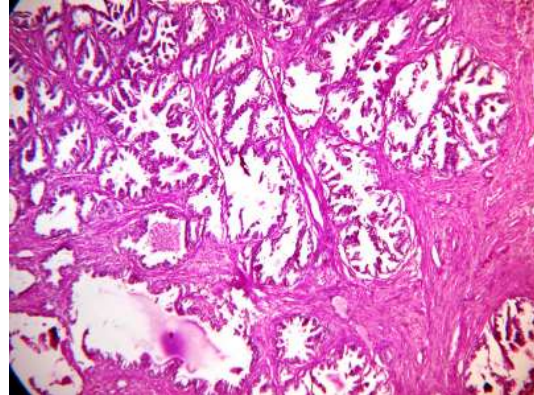


Figure 4: Ectopic prostatic tissue (H & E stain 400x)

Discussion

Ectopic prostatic tissue and seminal vesicle within pericolic fat is extremely rare.

Ectopic prostatic tissue has been reported at various sites within and outside the genitourinary system. In most of the cases it was observed in testis, seminal vesicle, epididymis, urinary bladder, uterine cervix and vagina.³ Very few cases involving retrovesical space, spleen and anal canal have been reported.

To the best of our knowledge, only a single case of ectopic seminal vesicle in scrotum has been reported in English literature.²

Our case is unique in that ectopia involved both prostatic tissue and seminal vesicle, observed in pericolic fat in a patient of rectal carcinoma creating a dilemma of metastasis.

Though some cases presented with symptoms such as hematuria, rectal bleeding, urethral obstruction etc., majority of ectopic tissue reported was an incidental finding as in our case. Histologically few cases revealed features of hyperplasia as seen in the present case.

The definite etiology of ectopic tissue is still not clearly known. Numerous different theories have been proposed such as faulty embryogenesis, migration or misplacement of normal tissue, persistence of embryonic remnants, metaplastic change caused by chronic inflammation⁴ and seeding of viable tissue to the rectum during surgery or biopsy.⁵

As most ectopic tissues are benign, endoresection has proven to be effective.⁶ In theory, ectopic tissue can undergo malignant transformation. The ectopic tissue in our case was benign. Even though the incidences of malignancy and recurrences are low follow up with endoscopic examinations are necessary.⁶

In summary, although clearly a rare occurrence, it is significant to note that seminal vesicle and prostatic ectopia can arise within the pericolic fat of rectum and may reflect divergent differentiation or a malformative process.⁴

Though less likely to turn to malignancy and difficult to interpret as given their rarity but may create a vexing clinical problem if not identified as being ectopic origin.¹

Seminal vesicle and prostatic heterotopia is significant in several respects, either symptomatic or asymptomatic, ectopic tissue can be endoscopically and histologically confused with malignancy in urinary or lower gastrointestinal system.

Proper identification of the ectopic tissue and not mistaking it for metastatic disease is important for accurate staging of rectal carcinoma.

References:

1. Fulton RS et al. Ectopic prostate, case report of a presacral mass presenting with obstructive symptoms. *Arch Pathol Lab Med.* 2001;125:286-288.
2. Patino GE, L'Esperance JO, Stroup SP, Snitchler AN, Auge BK. Ectopic Seminal Vesicle presenting as scrotal mass. *British Journal of Urology International.* Available at <http://www.bjui.co.uk/ContentFullItem.aspx?id=244&SectionType=4>
3. Rosai J. Rosai and Ackerman's Surgical Pathology, 10th edition. Mosby. 2011. pp. 1287-1288.
4. Fu-Qing Tan et al. An unusual case of retrovesical ectopic prostatic tissue accompanied by primary prostate cancer. *World Journal of Surgical Oncology.* 2012;10:186.
5. Xin-lin WU et al. Prostatic tissue ectopia in the rectum. *Chin Med J.* 2010;123(22):3372-3374.
6. Hung-Jen Shin et al. An unusual cause of distal ureteral obstruction. Ectopic prostatic tissue. *JTUA.* 2005;16:85-87.