



Case Report: **Retroperitoneal Ancient Schwannoma**

Authors

Nanda Patil, Associate Professor,
Shweta Joshi, Resident,
Dept. of Pathology, Krishna Institute of Medical Sciences Deemed University (KIMSDU), Karad, Maharashtra, India.

Address for Correspondence

Dr. Shweta Sainath Joshi,
'Shreyas' Bungalow, 54/A/39,
Plot no. 39-40, Shukrawar Peth,
Near Siddhanath Hospital,
Satara - 415 002,
Maharashtra, India.
E-mail: shwetajoshi4422@yahoo.com

Citation

Patil N, Joshi S. Retroperitoneal Ancient Schwannoma. *Online J Health Allied Scs.* 2014;13(1):9. Available at URL:<http://www.ojhas.org/issue49/2014-1-9.html>

Open Access Archives

<http://cogprints.org/view/subjects/OJHAS.html>
<http://openmed.nic.in/view/subjects/ojhas.html>

Submitted: Jan 23, 2014; Accepted: Apr 26, 2014; Published: May 15, 2014

Abstract: Schwannomas are rare tumors which arise from nerve sheath and are mostly benign in nature. They are usually located in the head, neck and flexor surfaces of extremities. Schwannomas are very rare in the retroperitoneal region. Amongst all schwannomas 0.7% of benign ones and 1.7% of malignant ones are located in the retroperitoneum. Preoperative diagnosis is difficult because of vague symptoms. We report a case of retroperitoneal schwannoma in a 70 years female patient because of its rarity and unusual location.

Key Words: Ancient schwannoma; Retroperitoneum

Introduction:

Schwannomas (Neurilemmas, Neurinomas or perineural fibroblastoma) are benign tumors arising from nerve sheath of Schwann cells. The etiology is still unknown.(1,2) They usually affect adult patients in the age group of 20-50 years and are more common in males.(3) The usual location is in head, neck and on flexor surfaces of extremities, retroperitoneum being the rare site with the incidence being 0.3-3.2%. Retroperitoneal schwannomas account for 1-10% of all primary retroperitoneal tumors.(1) Majority of retroperitoneal schwannomas are benign in nature. We describe a case of incidentally diagnosed retroperitoneal ancient type schwannoma in a female patient because of its rarity and unusual site.

Case Report

A 70 years female came to medicine department with complaints of epilepsy and vomiting. Ultrasonography revealed a round to oval heteroechoic mass near the lower pole of right kidney in the paracaval region. Other investigations were normal. Exploratory laparotomy was done, mass was excised and specimen was sent for histopathology.

Pathological examination: On gross examination it was a single, encapsulated, well-circumscribed, globular, grey

white to grey brown mass measuring 7x6x4 cm. Cut section revealed a grey white to grey brown variegated appearance with cystic areas, hemorrhages and areas of calcification. Microscopically it was a well circumscribed, encapsulated tumor showing hypercellular and hypocellular areas. Elongated spindle shaped neoplastic cells showed tapering nuclei with nuclear palisading. Occasional area showed enlarged, hyperchromatic nuclei with very low mitotic activity. Areas of cystic degeneration, myxoid change and ossification were noted.

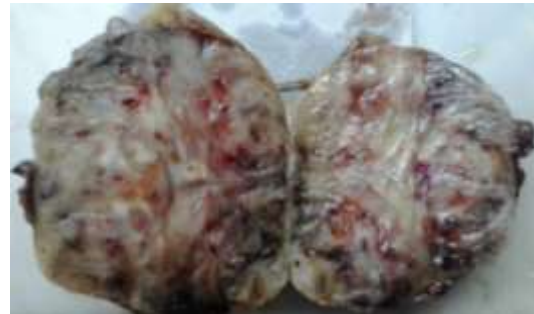

Figure 1: A well circumscribed tumour, cut section showing variegated appearance, cystic areas, hemorrhages and calcification

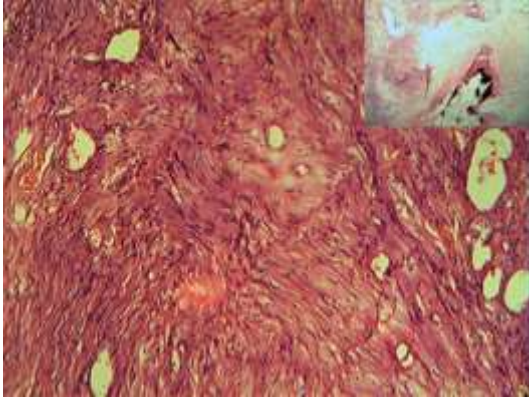


Figure 2: Tumor with hyper and hypocellular areas, nuclear palisading, cystic change. Inset: Ossification. 400x,H&E)

Discussion:

Retroperitoneal schwannomas are rare tumours and are usually detected incidentally after radiological examination. Neurological symptoms are rare. Few cases present with abdominal and lower back pain and digestive disturbances.

The tumour is usually detected with pre-operative cross sectional imaging which reveals a solid mass in the retroperitoneum with a few cystic areas. Though ultrasound and computed tomography can detect the tumour, MRI allows better visualization and involvement of other organs. These radiological findings are usually non-specific and fail to give accurate diagnosis on most of the times.(4) Definitive diagnosis relies on histopathological examination of the tumour. CT guided biopsy can be attempted for preoperative diagnosis. Kapan M stated the limited role of this investigation due to the risk of hemorrhages, infection and tumour seeding.

Complete surgical excision is the only treatment for these tumors as they are not sensitive to radiotherapy and chemotherapy.(3)

Prognosis of benign schwannomas is good. Only 5-10% cases show recurrence because of incomplete excision.(5)

Grossly schwannomas are encapsulated, globoid masses of variable size. Retroperitoneal schwannomas are usually large tumors. Cut section is glistening. Ancient schwannomas show infarct like necrosis, cystic changes, calcification and ossification related to degeneration.

Microscopically conventional schwannomas are composed of neoplastic schwann cells showing hyper and hypocellular areas, elongated cells with nuclear palisading.(6) Stroma shows thick walled dilated vessels. Ancient schwannomas show nuclear polymorphism including bizarre forms with nuclear inclusions and other secondary changes like calcification and ossification.(7)

Differential diagnosis include paraganglioma, pheochromocytoma, liposarcoma, malignant fibrous histiocytoma, retroperitoneal cystic masses such as hemangioma and lymphangioma.(1)

Immunohistochemistry is useful for confirmation of retroperitoneal schwannomas and markers are S-100 protein, Ki - 67, Leu - 7, Glial Fibrillary acidic protein in some cases.(7,8)

Conclusion:

Retroperitoneal ancient schwannomas are rare types of soft tissue nerve sheath tumors which are difficult to diagnose preoperatively due to vague symptoms. Definitive diagnosis relies on histopathology. CT guided FNAC should be tried to increase the accuracy of preoperative diagnosis. Treatment of choice is complete excision of mass. Recurrence and malignant transformation in retroperitoneal ancient schwannomas is rare.(5,9,10)

References:

1. Kalayci M, Akyuz O, Demirag A, Gurses B, Ozkan F, Gokce F. Retroperitoneal Schwannoma: A rare Case. *Case reports in Gastrointestinal Medicine*. 2011;2011:Article ID 465062. Available at <http://dx.doi.org/10.1155/2011/465062>
2. Aslan Y, Aydin AO, Tekdogan UY, Atan A. Retroperitoneal Schwannoma: A case Report Review of the literature. *Journal of Neurological Sciences*. 2010;27(3):353-358.
3. Wong CS, Chu TYC, Tam KF. Retroperitoneal schwannoma: a common tumour in an uncommon site. *Hong Kong Med J*. 2010;16:66-68.
4. Goh BKP, Tan Y, Chung YA, Chow PKH, Ool LPJ, Wong WK. Retroperitoneal schwannoma. *Am J Surg*. 2006;192:14-18.
5. Song JY et al. Schwannoma in the retro peritoneum. *J Obstet Gynaecol*. 2007;33:318-320.
6. Louis DN, Ohgaki H, Wiestler OD, Cavenease WK. Tumors of cranial and paraspinal nerves in WHO classification of tumours of the central nervous system. *IARC*. 2007;151-160.
7. Weiss SW, Goldblum JR. Benign tumours of peripheral nerves In Enzinger and Weiss's Soft Tissue Tumors. 4th edition. A Harcourt Health sciences company;2001, pp1111-1263.
8. Kudo T, Kawakami H, Kuwatani M, et al. Three cases of retroperitoneal schwannoma diagnosed by EUS-FNA. *World J Gastroenterol*. 2011;17(29):3459-3464.
9. Daneshmand S, Youssefzadeh D, Chamie K, Boswell W, Wu N, Stein JP et al. Benign retroperitoneal schwannoma: a case series and review of the literature. *Urology*. 2003;62(6):993-997.
10. Li Q, Gao C, Juzi JT, Hao X. Analysis of 82 cases of retroperitoneal schwannoma. *ANZ J Surg*. 2007;77(4):237-240.